

CLINICAL AND IMMUNOLOGICAL ASPECTS OF ELECTRICAL INSTABILITY OF A STRUCTURALLY UNCHANGED HEART

Peremot S. D., Volianskyi A. Y., Smlianska M. V.,
Kashpur N. V., Klysa O.O., Klysa T. L.

**Mechnikov Institute of Microbiology and Immunology
of the National Academy of
Medical Sciences of Ukraine**

Introduction. One of the most common forms of rhythm disturbance is a ventricular extrasystole (VES). When an ECG is recorded in 12 leads alone, ventricular extrasystoles are detected in about 5% of healthy young people, and in Holter ECG monitoring, within 24 hours, they are 50%. Although, it is worth noting, that most of them are represented by single extrasystoles. However, in some cases, complex forms, potentially malignant, with a high risk of sudden death can be detected [1].

According to studies, the prevalence of ventricular premature beats varies depending on the population studied, the duration of the observation and the method of its detection. According to the Framingham study, it was found that the prevalence of one or more ventricular extrasystoles per hour occurred in 33% of men and 32% of women without coronary heart disease (CHD) [2]. Among patients with coronary artery disease, the prevalence of one or more HPS was detected in 58% of men and 49% of women. Other studies using 24-hour monitoring showed the prevalence of VES in 41% of healthy boys - adolescents aged 14-16 years and in 50-60% of healthy young adults. These are the so-called "causeless" or "idiopathic" extrasystoles. The anatomical and histological substrate in these cases is still unclear. The data of various studies on this topic are contradictory and very variable.

The very concept of "idiopathic arrhythmias" is over 50 years old. In the scientific literature for the first time this term was fixed as "lone atrial fibrillation" [3]. Idiopathic is understood to mean arrhythmias with unidentified etiology in patients (usually younger than 60 years) without structural changes in the heart. This definition implies that all possibilities have been exhausted for diagnosing the cause of arrhythmia. However, in this case, the definitions of "arrhythmia of unknown etiology" or "primary electrical heart disease" are suggested. We use the term "idiopathic" in quotation marks, because it reflects only unrecognizability, but not the absence of, the cause of the arrhythmia as such. The literature published data on the absence of signs of any organic damage to the cardiovascular system in 10 to 30% of patients suffering from cardiac rhythm disturbances. As for today, "idiopathic arrhythmia" is the main cause of sudden cardiac death at a young age [4]. Thus, the peak incidence of ventricular extrasystole is observed at the age of 30 - 35 years, and in cases of fatal tachyarrhythmias - at 25. Unfortunately, there is no epidemiological data on vital rhythm disturbances in young people without organic heart damage in Ukraine [5].

The active introduction into clinical practice of highly informative instrumental methods of myocardial

examination, specific immunological tests and molecular genetic methods of investigation is the basis for revealing the hidden causes of their occurrence. The data of autopsy of suddenly died persons who did not have diseases of the cardiovascular system, diagnosed during life, were published. In a number of cases, signs of inflammation and fibrosis of the myocardium have been revealed, which may be a manifestation of latent myocarditis, which "debuted" as fatal ventricular arrhythmia [6]. Studies of myocardial biopsy specimens in sudden dead young people indicate the presence of myocarditis in 2-42% of cases [7, 8]. However, in most cases the etiological factor of inflammatory myocardial damage remains undefined. Among the potential causative agents of latent inflammatory processes, which also have the capacity for panthropy and persistent persistence, the main place is occupied by cardiotropic viruses from the Herpesviridae family. And until now, viral myocarditis remains a little-studied disease, since a viral infection that can cause a latent inflammatory process and in 24% - 33% of patients is difficult to identify [9]. In addition to direct changes in the electrophysiological properties of cardiomyocytes as a result of damage, interstitial myocardial edema and the appearance of foci of necrosis and fibrosis of the myocardium, as well as the development of a secondary pathological immune response, may lead to the formation of zones of electrical instability.

That is why the search for clinical and instrumental, laboratory indicators of inflammation in young people without structural damage to the cardiovascular system with signs of electrical instability is relevant for solving the problem of timely diagnosis and treatment of threatening ventricular arrhythmias.

The aim of the study was to search for clinical and instrumental signs of inflammation and markers of herpesvirus infection in persons with ventricular ectopic activity without structural damage to the cardiovascular system.

Material & methods. Twenty-three patients (14 men and 9 women) were involved in the study based on the results of 24-hour Holter monitoring with no signs of an organic disease of the cardiovascular system at the age of 17-35 years (mean age $25,7 \pm 6,9$ years). Only patients with class 3 and higher according to the classification of B.Lown, M.Wolf, in the modification M. Ryan (1975) were recruited into the group of patients examined. Exclusion criteria were the presence of significant coronary artery disease (defined as the presence of > 50% luminal stenosis on coronary angiography), myocarditis, severe valvular heart disease, and/or chronic renal failure (estimated glomerular filtration rate < 30 ml/min). All patients underwent an echocardiographic study of the heart. The analysis of the results showed that the size of the left heart chambers and the global contractile ability of the left ventricle (LV), on average, were within normal limits. All tapes were analyzed without knowledge of the patients' clinical status or the results of the other investigations. Relevant clinical parameters derived from general laboratory analyses, electrocardiography, and echocardiography were recorded at baseline. Baseline data were collected with patients in a clinically stable condition. The control group consisted of 16 practically healthy

persons, comparable in age and gender ratio with the main group of subjects.

In order to verify the inflammatory process in the myocardial tissues, the subjects underwent magnetic resonance imaging (MRI) of the heart with intravenous contrast and to determine the degree of viral load of the blood cells of the participants in the Herpesviridae family (HHV_{1,2}, HHV₃, HHV₄, HHV₅, HHV₆). Herpesviruses are capable of prolonged persistence not only in immunocytes, but also in the vascular endothelium, myofibrils and cells of the nervous system. The study was carried out using fluorescent antibodies using specific monoclonal antibodies from Santa Cruz Biotech. Inc. (USA). The degree of viral load was determined using a photometric packing, by calculating the difference between the average level of fluorescence of damaged cells and background indices and expressed in conventional fluorescence units (CFU).

In order to confirm the latent inflammatory process, the levels of pro-inflammatory cytokines: interleukin 6 (IL6) and tumor necrosis factor α (TNF- α) were studied by enzyme-linked immunosorbent assay. The "IFABEST" test systems of CJSC "Vector-Best" and Stat-Fax -303 immunoassay analyzer (USA) were used. The determination was carried out in accordance with the instructions.

The statistical treatment was performed using Statistica 11.0 (StatSoft, Inc). To determine the reliability of the differences between the indexes in the studied samples, the non-parametric Mann-Whitney's criterion was used, while the Student's T-criterion was used for the normal distribution, $P < 0.05$ was considered statistically significant.

Results & discussion. As a result of the study, the markers of herpesviruses in blood immunocytes, both in the form of a monoinfection and in a mixed infection, were found in 20 patients with ventricular extrasystole, which was almost 87%, while in the control group, similar markers were found in 4 subjects (25 % of cases). The results indicate for the presence of a latent virus infection. Moreover, the degree of viral load in the group of patients

with ventricular ectopic activity averaged 1.4 - 1.8, CFU, which corresponds to the average and high level, but in the control group did not exceed 1.2 CFU, which corresponds to a low degree of viral load.

HHV_{1,2}, HHV₅ and HHV₃ were the most common representatives of Herpesviridae. Moreover, a combination of three or more viruses was simultaneously noted in 52.2% of patients. The fact that one of the most frequently detected herpes viruses was HHV3 deserves special attention. It is this member of the family Herpesviridae that possesses high neuropathogenicity and transneuronal dissemination ability.

It should be noted that in the control group, a herpetic monoinfection was observed in three cases and only one was a combination of HHV1, 2 HHV6. The simultaneous presence of several antigens of different types of herpesviruses in immunocytes may be a condition not only for herpesvirus persistence, but also serve as an indirect confirmation of a possible latent inflammatory process. Laboratory and clinical studies have shown that there are at least two major proinflammatory cytokines released by virus-induced cell damage: IL6 and TNF α . Antigenic stimulation in the host leads to the secretion of "first wave" cytokines (IL6, TNF α and IL1), which in turn induce a further cascade of inflammatory mediators and ultimately form an immunological response. In addition, plasma levels of cytokines can serve as prognostic criteria for the outcome of the disease.

To test this assumption, the levels of the main inflammatory mediators from the group of proinflammatory interleukins IL-6 and TNF- α were studied by ELISA. The concentration of mediators of inflammation in the blood serum of patients with idiopathic rhythm disturbances without structural damage to the heart was significantly higher than in the control group, which indicates the inflammatory process in these patients (Figure). Moreover, the concentration of TNF- α in ventricular rhythm disturbances was almost 18.5 times higher than the corresponding control group, and the level of IL-6 exceeded the control one by almost 7 times.

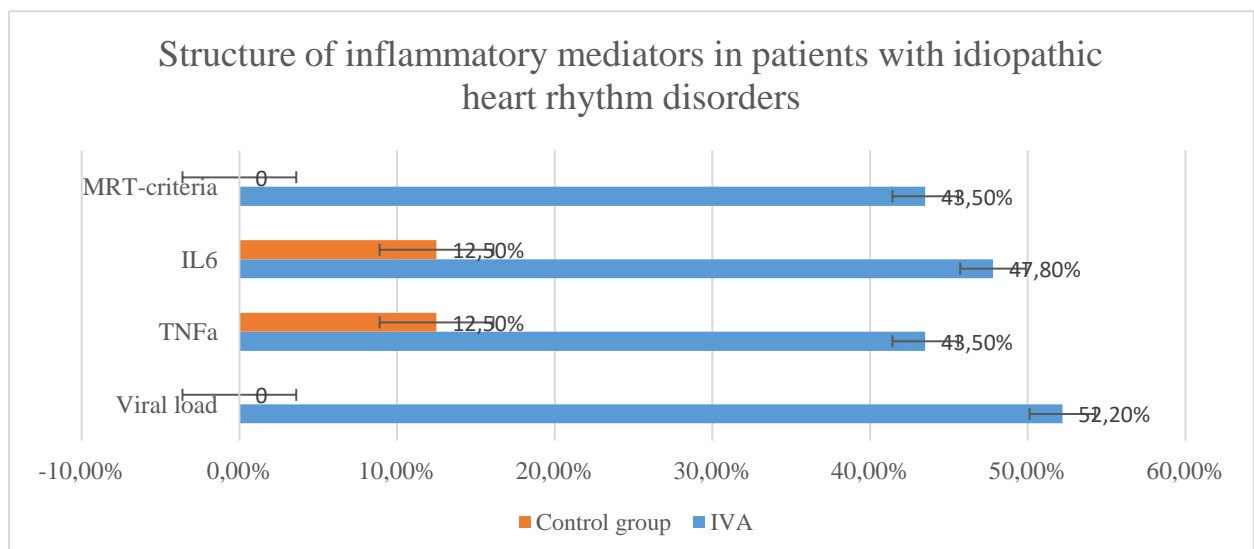


Fig. The presence of inflammatory markers in patients with idiopathic ventricular arrhythmia.

The obtained data on the concentration of mediators of inflammation in the blood serum and the results of virologic research testify to the latent inflammatory process of herpesvirus nature in the corresponding percent of subjects with ventricular arrhythmias. However, to confirm or refute this assumption, it is necessary to conduct studies that would allow visualizing the foci of inflammation of cardiomyofibril and the tissues that surround them.

Of the primary imaging modalities (radiography, ultrasound, computed tomography, nuclear medicine, magnetic resonance), magnetic resonance imaging (MRI) is the most novel of the five used today. Despite the longer time and higher costs, which limit its use, the lack of ionizing radiation makes MRI attractive. For this reason, many research initiatives are aimed at expanding the role MRI has in modern medicine. Cardiac magnetic resonance (CMR) is a powerful tool to evaluate the anatomic substrate of ventricular arrhythmias. Myocarditis is a frequent cause of a arrhythmias, and is properly diagnosis by CMR. The sensitivity of this method to detect inflammatory changes in the heart muscle when comparing T1, T2-weighted and T1-weighted delayed images reaches 78%, and the specificity reaches 100%.

Therefore, to confirm the inflammatory process in the myocardium of the subjects, MRI was performed in three standard methods: assessment of myocardial edema in a T2-weighted image, and early (EC) and late contrasting (LC). Cardiac magnetic resonance imaging was performed in the clinic for adults Center for Pediatric Cardiology and Cardiac Surgery (Kyiv). Edema in T2-weighted images was visualized in 2 to 4 segments of different locations of 9 (39,1 %) subjects. When assessing EC on T1-weighted images, signal strength intensification was from 3 to 5 segments in 47.8% of patients with rhythm disturbances. Moreover, the zones of hyperemia in the subjects were located mainly in different segments of the left ventricle. Most often it was the subvalvular zone of the upper third of the left ventricle and the zone of the left coronary artery. In some cases, the zone of hyperemia coincided with the zone of edema or late contrast. In the PC phase, 7 patients had different types of cells, including transmural cells, and the number of damaged segments ranged from 1 to 6, which averaged almost 14% of the myocardium. Proceeding from the fact that the criterion of inflammatory myocardial damage is the presence of two inflammatory phenomena, we analyzed the data obtained in accordance with this criterion. It turned out that among patients with idiopathic ventricular arrhythmias two or more positive phenomena were registered in 10 (43.5%) patients. And, in two of them, all three MRI-criteria for inflammation were noted. Obtained MRI data of individuals with ventricular arrhythmias correlate with data from studies of levels of pro-inflammatory interleukins in this group. This fact also argues in favor of the inflammatory component in the pathogenesis of electrical instability of the structurally unchanged heart. It is this hidden, latent process that "debuts" with the ventricular extrasystole, which carries the threat of a decrease in myocardial contractility due to late diagnosis and, as a consequence, the lack of adequate treatment.

It should be noted that the results of our pilot study raise more questions than answers and dictate the need to continue research in order to find diagnostic markers of electrical instability and their risk stratification, but also further in-depth correlation analysis. Thus, the obtained results of the conducted studies indicate that the basis of non-coronarogenic ventricular ectopic activity can be ectopic foci of excitation caused by a latent herpesviral inflammatory process in the myocardium, and MRI criteria for inflammatory foci in combination with elevated levels of TNF- α and IL-6 – as additional markers of subclinical myocarditis in patients without structural heart damage.

References

1. Makarov L.M. Holter monitoring in the examination of patients with rhythm disturbances / L.M. Makarov, V.N. Komolyatova // Clinical arrhythmology; Edited by A.V. Ardashev. - M.: Medpraktik. 2009. P. 119-156.
2. Genetics of the Framingham Heart Study Population / D. R. Govindaraju [et al.] / Adv. Genet. – 2008. – Vol. 62. – P. 33–65.
3. Evans W., Swan P. Lone auricular fibrillation // Br. Heart J. 1954. № 16 (2). P. 189 – 94. URL: <https://www.ncbi.nlm.nih.gov/pubmed/13160271-u.pdf> (request date 27.09.2018).
4. Corrado D., Basso C., Rizzoli G. [et al.] Does sports activity enhance the risk of sudden death in adolescents and young adults? // J. Am. Coll. Cardiol. 2003. Vol. 42. - P. 1959–1963.
5. Sudden cardiac death: risk factors and prevention: Recommendations of the Ukrainian Scientific Society of Cardiology - Kiev, 2003. – 75 c.
6. Ellis C.R, Salvo T.D. Myocarditis. Basic and Clinical Aspects. Cardiology in Review. 2007; 15: 170-7.
7. Strain J.N., Grose R.M., Factor S.M. [et al.] Result of endomyocardial biopsy in patients with spontaneous ventricular tachycardia but without apparent structural heart disease // Circulation. 1983. №6. P. 1171-1181. URL: <https://www.ahajournals.org/doi/abs/10.1161/01.cir.68.6.1171-u.pdf> (request date 12.09.2018).
8. Sergeeva V.A., Shmoylova A.S.. Clinical manifestations of infectious myocarditis in men and women // Clinical. 4'2016/1'2017. Vol. 10|11. P. 45-49. URL: <https://klinitsist.abvpress.ru/Klin/article/viewFile/291/260-u.pdf> (request date 12.09.2018).
9. Kovalenko V.N., Nesukai Ye.G, Cherniuk S.V. Myocarditis: a contemporary look on the etiology and pathogenesis of the disease // Ukrainian Journal of Cardiology. 2012. № 2. P. 84-91.

CLINICAL AND IMMUNOLOGICAL ASPECTS OF ELECTRICAL INSTABILITY OF A STRUCTURALLY UNCHANGED HEART

Peremot S. D., Volianskyi A. Y., Smilianska M. V., Kashpur N. V., Klysa O.O., Klysa T. L.

Introduction. The concept of "idiopathic ventricular arrhythmias" (IVA), i.e. arrhythmias that have arisen in the absence of structural disorders of the heart, is becoming more and more conventional. As for today, "idiopathic arrhythmia" is the main cause of sudden cardiac death at a young age. Unfortunately, there is no

epidemiological data on vital rhythm disturbances in young people without organic heart damage in Ukraine. The active introduction into clinical practice of highly informative instrumental methods of myocardial examination, specific immunological tests and molecular genetic methods of investigation is the basis for revealing the hidden causes of their occurrence. **The aim of the study** was to search for clinical and instrumental signs of inflammation and markers of herpesvirus infection in persons with ventricular ectopic activity without structural damage to the cardiovascular system. **Material & methods.** Twenty-three patients (14 men and 9 women) were involved in the study based on the results of daily monitoring (1200 ventricular ectopic complexes per day) with no signs of an organic disease of the cardiovascular system at the age of 17-35 years (mean age 25.7 ± 6.9 years). The control group consisted of 16 practically healthy persons, comparable in age and gender ratio with the main group of subjects. All examined patients underwent daily monitoring of ECG and blood pressure by Holter using 12 channel monitors. The study used the results of magnetic resonance imaging of the heart with intravenous contrast and determination of the viral load representatives of Herpesviridae (HHV1, 2, HHV3, HHV4, HHV5, HHV6). The study was carried out using fluorescent antibodies using specific monoclonal antibodies from Santa Cruz Biotech. Inc. (USA). The levels of the main inflammatory mediators from the group of proinflammatory interleukins IL-6 and TNF- α were studied by ELISA, using commercial Thermo Scientific™ kits (USA). **Results & discussion.** As a result of the study, the markers of herpesviruses in blood immunocytes, both in the form of a monoinfection and in a mixed infection, were found in 20 patients with ventricular extrasystole, which was almost 87%, while in the control group, similar markers were found in 4 subjects (25 % of cases). Moreover, the degree of viral load in the group of patients with ventricular ectopic activity averaged 1.4 - 1.8, CFU, which corresponds to the average and high level, but in the control group did not exceed 1.2 CFU, which corresponds to a low degree of viral load. Viruses: HHV_{1,2}, HHV₅ and HHV₃ were the most common representatives of Herpesviridae in 52% of patients with idiopathic ventricular arrhythmias. The obtained data of levels of pro-inflammatory cytokines suggest the presence of an inflammatory process that is not accompanied by severe clinical manifestations. So the concentration of mediators of inflammation in the blood serum of patients with idiopathic rhythm disturbances without structural damage to the heart was significantly higher than in the control group, which indicates the inflammatory process in these patients. The concentration of TNF- α in ventricular rhythm disturbances was almost 18.5 times higher than the corresponding control group, and the level of IL-6 exceeded the control one by almost 7 times. Recently, due to the introduction into clinical practice of modern methods of visualization of myocardial damage of both coronary and non-coronary genesis, it has become possible to non-invasively identify various signs of a latent inflammatory process. According to the Lake Louise Criteria (LLC), magnetic resonance imaging (MRI) is now recognized as a noninvasive

diagnostic method for verifying myocarditis. When assessing early contrasting on T1-weighted images, signal strength intensification was from 3 to 5 segments in 47,8 % of patients with rhythm disturbances. Confirmation of inflammation of the myocardium is the presence of two criteria. It turned out that among patients with idiopathic ventricular arrhythmias two or more positive phenomena were registered in 10 (43.5%) patients. Obtained MRI data of individuals with ventricular arrhythmias correlate with data from studies of levels of pro-inflammatory interleukins in this group. **Conclusion.** Thus, the obtained results of the conducted studies indicate that the basis of non-coronarogenic ventricular ectopic activity can be ectopic foci of excitation caused by a latent herpesviral inflammatory process in the myocardium, and MRI criteria for inflammatory foci in combination with elevated levels of TNF- α and IL-6 – as additional markers of subclinical myocarditis in patients without structural heart damage.

Keywords: idiopathic ventricular arrhythmias, criteria for inflammatory process, herpesviruses.