

UDC: 616.9-616.037-616.127-002

MOLECULAR BIOLOGICAL RESEARCH AT FATAL CONSEQUENCES OF VIRAL MYOCARDITIS

Smelyanskaya M. V., Peremot S. D., Kashpur N. V.,
Volanskiy A. Y.

National academy of medical sciences of Ukraine
Mechnikov institute of microbiology and immunology

Diagnosis of viral myocarditis, based on the evidence base, is still one of the key problems of the heart disease. In practice the instrumental methods of examination of patients are used, the search for new possibilities of non-invasive methods is conducted to assess the presence of inflammatory processes in the myocardium. The disease begins with cold or influenza-like infection in the majority of patients, and it is almost always ignored by both the patients and attending physicians. This situation is due not only to low doctors' awareness, but also with a variety of clinical manifestations of this disease. At the same time, in many cases myocarditis can proceed without significant clinical manifestations and be undiagnosed. Molecular analysis detects the presence of a viral infection in 65% of people who suddenly died. Also it is proved that the cause of almost 20% of cases of sudden deaths of physically safe people is myocarditis. The presence of morphological features of the inflammatory process makes it possible to confirm the diagnosis of myocarditis, but, at the same time, the absence of these features is not sufficient to remove this diagnosis. In routine postmortem study of deaths in multidisciplinary (non-infectious) hospital myocarditis is stated as a cause of death in 0.2-0.4% of all the autopsies. Mortality in myocarditis depends on the severity of the underlying disease, premorbid background, age and sex

composition of the patients. According to different authors, it is very different and ranges from 0.03 to 26% [1].

Adenoviruses, enteroviruses parvovirus and 19 are the most frequently mentioned in patients with viral myocarditis. However, there are geographical variations in the detection of viral genomes identified with myocarditis [2]. Thus, in recent years parvovirus B-19 and human herpes virus 6 were the most common viral genome detected in myocardial biopsies in the European population. During these years, in a population of indigenous Japanese the frequency of detection hepatitis C virus genome has sharply increased.

Interestingly, in the European population frequency of detecting cytomegalovirus, herpes simplex virus and Epstein-Barr virus has decreased, but the association of 2 or more virus increased to 25% [3].

The aim of the work was to carry out histological and molecular biological studies postmortem material for confirming the etiologic role of herpesviruses with fatal consequences of infectious myocarditis during the observation period 2015-2016 years.

Materials & methods

The material of pathological heart, vascular endothelium, nerve ganglia, kidneys, liver and pancreas were investigated. Viral antigen detection was performed by fluorescent antibody technique with specific sera labeled with FITC (Dako Corporation, Carpinteria, CA) and detection of the viral genome by PCR (in SYNEVO Laboratory). Morphological studies have been conducted in the post-mortem offices of the Kharkov clinical hospitals. Histological specimens were studied under the light microscope when stained with hematoxylin-eosin and Movat [4]. For histological confirmation of the diagnosis "myocarditis" ("certain" myocarditis) was considered necessary and sufficient to identify a material such morphological traits: 1) inflammatory cellular infiltrate and 2) cardiomyocyte necrosis or damage (Fig. 1).

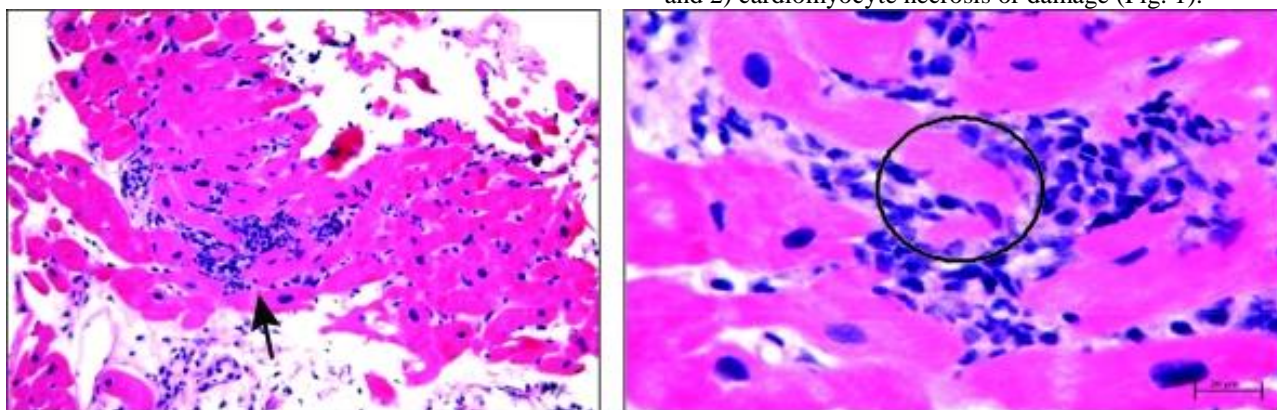


Figure 1. Endomyocardial biopsy. On the left, there is the diffuse lymphocytic infiltration of the myocardium (arrow). On the right, there is the lymphocytic infiltration with myocyte damage and surrounding myocardial edema (circle) [5].

Isolation of DNA from heart and other tissues was performed using DNA mini kit (Qiagen) after deparaffination with xylene and ethanol washing. The pellet was resuspended in 180 μ l of lysis buffer ATL and 20 μ l of proteinase K and incubated at 56 $^{\circ}$ C overnight. Further manipulations were performed according to the manufacturer's instructions. DNA was eluted in 100 μ l of AE buffer and stored at -20 $^{\circ}$ C.

Detection of viral genome was performed by PCR using certified commercial kits for detection of nucleotide sequences of herpesviruses «HSV I, II-EPh», «VZV-FL», «EBV-EPh», «CMV-EPh», «HHV VI-Eph», («AmpliSens»). Diagnosis was made in FRT «real time» using modern six-channel thermocycler «Rotor Gene

6000» (Qiagen, Germany) in laboratories "B.A.T." and "Synevo".

Determination of herpesvirus antigens (Ag) was carried out by using a fluorescent antibody with specific monoclonal mouse antibodies company Santa Cruz Biotechnology, Inc. (USA) and LLC "CPDP" supplier which was LLC "Bio Test Med" (Kiev, Ukraine).

The first group consisted of 19 people who died from infectious myocarditis (IM) (group 1). The second group (group 2) consisted of 22 dead from complications of other cardiovascular disease (CVD). Pathoanatomical material of 11 people was used as a control group. Death in this group occurred as a result of traumatic injuries. The average age of those groups was $31 \pm 3,8$ years. All groups were matched by sex and age.

Results & discussion

Firstly, the presence of nucleic acids – NA (DNA or RNA) in the myocardial tissue of the dead from different groups was analyzed (Fig. 2). It has been found, that DNA HSV1, 2 turned out in IM group and in the group with the same frequency CVD. Whereas DNA HHV6 and CMV appeared in IM group 6-7 times more often. Noteworthy the DNA VZV finding of a significant percentage of myocardial tissue samples of the dead from group 1 in relation to other groups. According to our data, which coincides with the tendency of foreign research, the proportion of finding enteroviruses, compared with herpesviruses, is insignificant in all the groups.

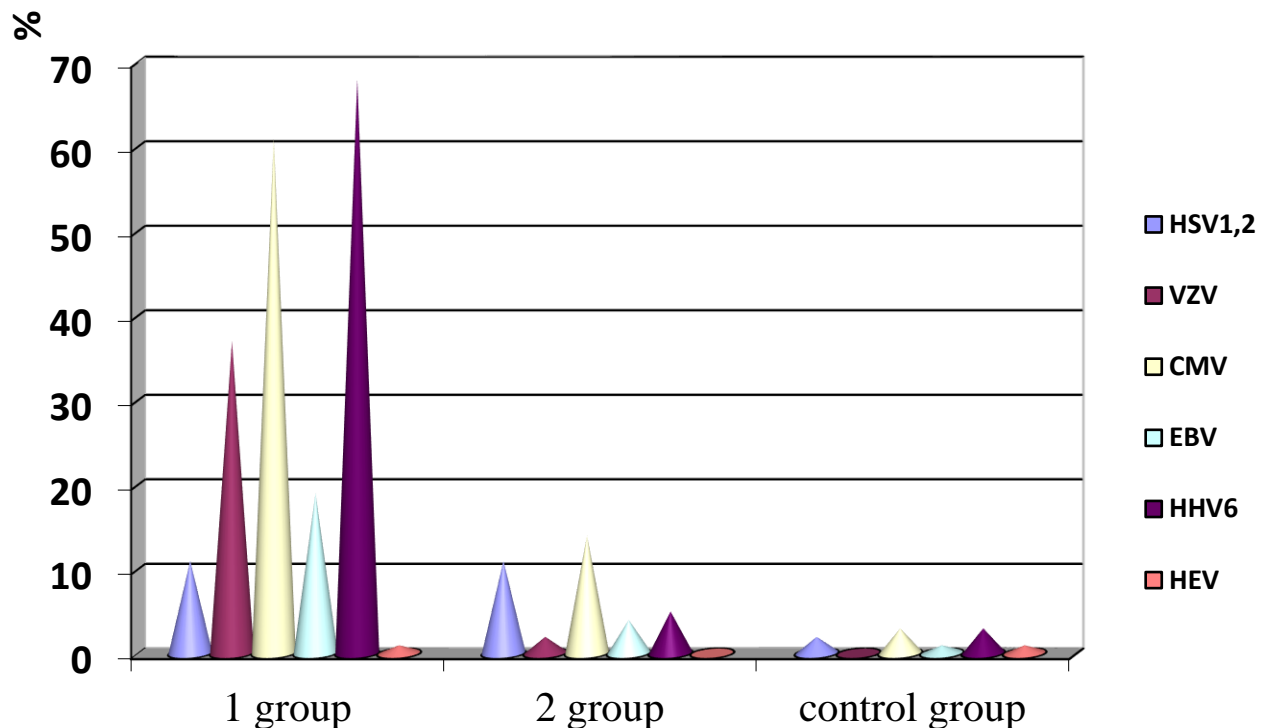


Figure 2. Detection of (PCR) NA viruses in the myocardium of dead of various groups.

Thus, HHV6 and CMV, VZV and EBV most frequently appear in myocardial tissue from deceased patients with viral myocarditis.

It is unquestionable fact that the latent viral infection maintains chronic inflammation affects the functional state of the immune system, etc. Chronic implicit immune deficiency may contribute to the immunity's inability to eliminate the viral agents from the body. The ability of herpes viruses for a long persistence in the various organs and tissues necessitates search Ag herpesviruses in various internal organs of the dead from the IM. Therefore, our data Ag presence of viruses in various internal organs were analyzed (Fig. 3). In all of the dead of the main group (IM) herpes viruses have been detected in several organs simultaneously. Also infarction hypertension virus is most often in the liver, pancreas and nerve ganglia. Thus, in some dead HBV antigens were detected only in one body, in others - in several organs simultaneously. Also, representatives of the herpesvirus

family markers were found in diverse percentage in organs, which were investigated. Thus, when HSV was expected in the nerve ganglia, kidney and vascular endothelium, the detection of a relatively high percentage of hypertension HHV6, CMV and, especially, VZV was quite unexpected in the pancreas and liver tissues. Detection of different herpes viruses in various organs confirms the pantropism of viruses of this family. And the persistence of the virus in one of the bodies makes it possible to its participation in the etiopathogenesis of infectious myocarditis.

The results indicate that in humans, especially with chronic somatic diseases, with high probability, in one or more organs is representative persistent herpesvirus group. Any stress on the body, as the exacerbation of physical illness, surgery, infectious diseases, sudden changes in diet, changes in social conditions, etc. there are conditions for reactivation, demonstration and dissemination of a latent herpes infection.

Ignoring the fact of the persistence of viruses in the appointment of complex treatment may not give the

desired result and lead to unpredictable virus-induced complications and consequences of this disease.

Analysis of the detection of mono- and mixed infection in the groups that were studied showed that in the control group with mono infections are twice more often than in the second group, and almost four times more than in the first group.

In addition, the combination is not revealed three or more viruses in the control group at the same time. In contrast, in the group with IM 3-4 viruses and 5 or more viruses appeared significantly more often in comparison with the group with CVD in two and 4,5 times, respectively (table 1).

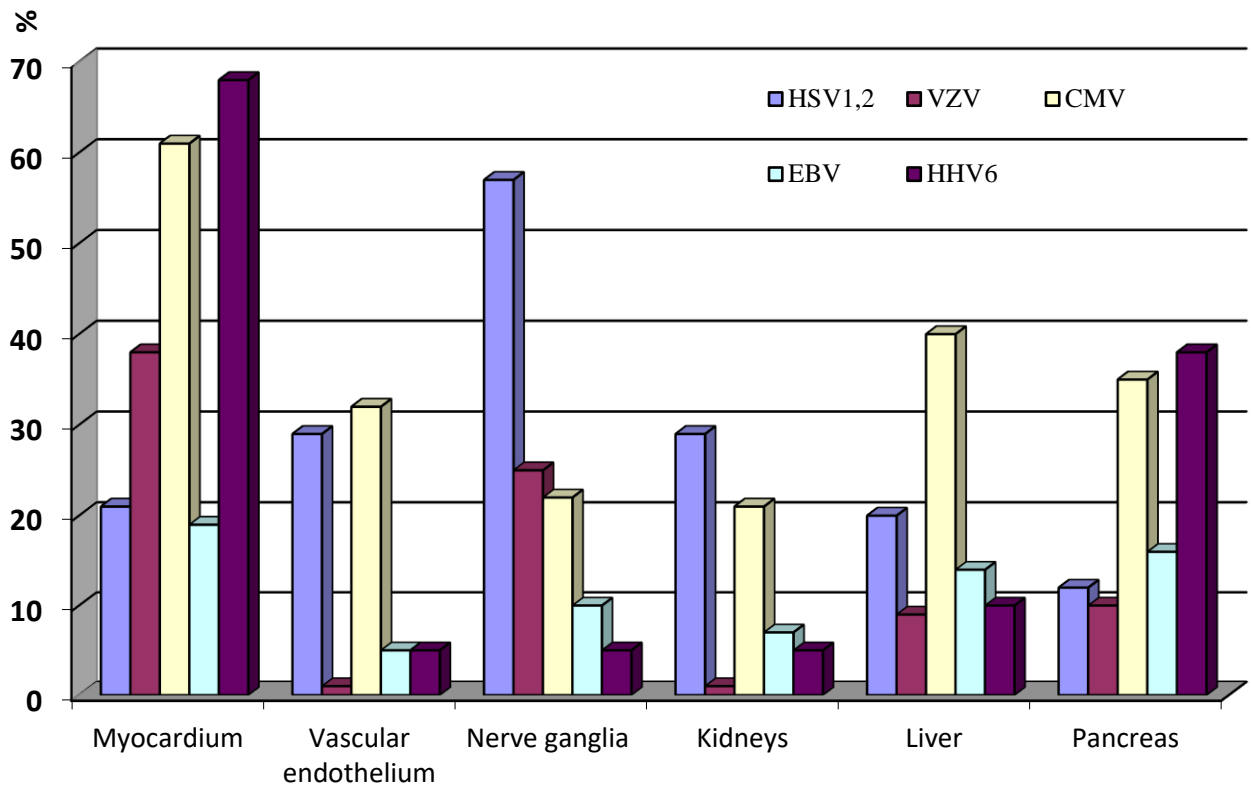


Figure 3. Detection Ag herpes virus in some dead bodies on IM

Table 1. Percentage of detection of mono and mixed herpesvirus infections

Groups	Mono infection	2 -3 viruses	3-4 viruses	5 and more viruses
1 group	23 ± 1,97 ¹⁾	36 ± 2,65 ¹⁾	27 ± 1,38 ^{1) 2)}	14 ± 1,67 ^{1) 2)}
2 group	45 ± 2,12 ^{1) 2)}	41 ± 2,02 ¹⁾	13 ± 1,34 ¹⁾	3 ± 0,25
Control	90 ± 4,25	10 ± 1,32	0	0

Notes: 1) - the differences were significant compared to the control group (p <0,05) 2) - differences are significant as compared with the 1 and 2 groups of children with HGVI (p <0,05).

In our opinion, in a mixed viral infection it is assumed that one type of virus may increase the virulence of other viruses (especially in the same family of herpes viruses), mainly due to the overall cell receptors. And these mixed infections are associated with the deterioration of left ventricular function and prognosis in general.

Conclusion

In deceased patients with viral myocarditis HHV6 and CMV, VZV and EBV are most often found in the myocardial tissue.

In all of the dead of the main group (IM) herpes viruses have been detected in several organs

simultaneously. Besides the myocardium, Ag viruses is mostly found in the liver, pancreas and nerve ganglia.

In the group with IM 3-4 Viruses and more occurred at the same time significantly more compared to the group CVD: two and 4.5 times, respectively. This may increase the virulence of the various representatives of herpesviruses from general cell receptors.

Development and introduction into medical practice new informative methods for diagnosis of myocarditis and clarify their etiology, perhaps, will enable viral myocarditis seen as a much more common pathology than is currently available. As stated in the official materials of the Congress of the European Society of Cardiology (Munich, August 30 - September 3, 2008) [6] to date information on the treatment and prevention of

cardiovascular disease in our country is very low, including in comparison to our nearest neighbors - countries with roughly the same economic and political problems, as in Ukraine, as well as with similar principles of health service organization. Adverse trends in the dynamics of cardiovascular morbidity and mortality, and the prevalence of major risk factors give rise to European experts to talk about Ukraine more often as the most significant negative example. And the gradient differences on key indicators between the countries of Western, Southern and Northern Europe, on the one hand, and Central and Eastern Europe - on the other, it is largely determined by disappointing data on Ukraine. This is a serious reason to think all Ukrainian physicians and health care managers. One can only hope that these statistics can be a major factor driving the necessary changes in our country. One thing is clear - to reverse these negative trends, the Ukraine is already waiting for a very large and complex work, and more and the work becomes more difficult and costs us all more expensive (and in economic terms, and in terms of human lives).

UDC: 616.9-616.037-616.127-002
MOLECULAR BIOLOGICAL RESEARCH AT
FATAL CONSEQUENCES OF VIRAL
MYOCARDITIS

Smelyanskaya M. V., Peremot S. D., Kashpur N. V., Volanskiy A. Y.

Introduction. Diagnosis of viral myocarditis, based on the evidence base, is still one of the key problems of the heart disease. The presence of morphological features of the inflammatory process makes it possible to confirm the diagnosis of myocarditis, but, at the same time, the absence of these features is not sufficient to remove this diagnosis. In routine postmortem study of deaths in multidisciplinary (non-infectious) hospital myocarditis is stated as a cause of death in 0.2-0.4% of all the autopsies. Mortality in myocarditis depends on the severity of the underlying disease, premorbid background, age and sex composition of the patients. According to different authors, it is very different and ranges from 0.03 to 26%. The aim of the work was to carry out histological and molecular biological studies postmortem material for confirming the etiologic role of herpesviruses with fatal consequences of infectious myocarditis during the observation period 2015-2016 years. **Material & methods.** The material of pathological heart, vascular endothelium, nerve ganglia, kidneys, liver and pancreas were investigated. Viral antigen detection was performed by fluorescent antibody technique with specific sera labeled with FITC (Dako Corporation, Carpinteria, CA) and detection of the viral genome by PCR (in SYNEVO Laboratory). Morphological studies have been conducted in the post-mortem

offices of the Kharkov clinical hospitals. Detection of viral genome was performed by PCR using certified commercial kits for detection of nucleotide sequences of herpesviruses «HSV I, II-Eph», «VZV-FL», «EBV-EPh», «CMV-EPh», «HHV VI-Eph», («AmpliSens»). Diagnosis was made in «real time» using modern six-channel thermocycler «Rotor Gene 6000» (Qiagen, Germany). The first group consisted of 19 people who died from infectious myocarditis (group 1). The second group (group 2) consisted of 22 dead from complications of other cardiovascular disease. Pathoanatomical material of 11 people was used as a control group. Death in this group occurred as a result of traumatic injuries. The average age of those groups was $31 \pm 3,8$ years. All groups were matched by sex and age. **Results & discussion.** It has been found, that DNA HSV1,2 turned out in infectious myocarditis group and in the group with the same frequency cardiovascular disease. Whereas DNA HHV6 and CMV appeared in infectious myocarditis group 6-7 times more often. Noteworthy the DNA VZV finding of a significant percentage of myocardial tissue samples of the dead from group 1 in relation to other groups. According to our data, which coincides with the tendency of foreign research, the proportion of finding enteroviruses, compared with herpesviruses, is insignificant in all the groups. In all of the dead of the main group (infectious myocarditis) herpes viruses have been detected in several organs simultaneously. Also infarction hypertension virus is most often in the liver, pancreas and nerve ganglia. Thus, when HSV was expected in the nerve ganglia, kidney and vascular endothelium, the detection of a relatively high percentage of hypertension HHV6, CMV and, especially, VZV was quite unexpected in the pancreas and liver tissues. Detection of different herpes viruses in various organs confirms the pantropism of viruses of this family. And the persistence of the virus in one of the bodies makes it possible to its participation in the etiopathogenesis of infectious myocarditis. **Conclusion.** In deceased patients with viral myocarditis HHV6 and CMV, VZV and EBV are most often found in the myocardial tissue. In all of the dead of the main group (infectious myocarditis) herpes viruses have been detected in several organs simultaneously. Also infarction hypertension virus is most often in the liver, pancreas and nerve ganglia. In the group with infectious myocarditis 3-4 viruses and 5 or more viruses appeared significantly more often in comparison with the group with cardiovascular disease in two and 4,5 times, respectively. This may increase the virulence of the various representatives of herpesviruses from general cell receptors.

Keywords: herpesviruses, myocarditis, PCR

References:

1. Russian Scientific Medical Society of Therapists' and Society of Specialists in Heart Failure's recommendations for the diagnosis and treatment of myocarditis (<http://www.ingorts.ru/index.php/ru/national-guidelines>)
2. Toshitaka Yajmia. Viral myocarditis: potential defense mechanisms within the cardiomyocyte against virus

infection// Future Microbiol. 2011; Vol. 6: 551–566. doi: 10.2217/fmb.11.40
3.<http://www.ingorts.ru/index.php/ru/national-guidelines>
4 .Kyto V., Vuorinen T., Saukko P., Lautenschlager I., Lignitz E., Saraste A., Voipio-Pulkki L.M.Cytomegalovirus infection of the heart is common in

patients with fatal myocarditis// *Clin Infect Dis.* 2005. 40(5). P. 683-688

5. Schultz J. C., Hilliard A. A., Cooper L. T, et al. *Diagnosis and Treatment of Viral Myocarditis// Mayo Clin Proc.* 2009. 84(11). P. 1001–1009. doi: 10.1016/S0025-6196(11)60670-8

6 . Official documents of the Congress of the European Society of Cardiology (Munich, August 30 - September 3, 2008)