

UDC 616.133-007.271-089.87

<https://doi.org/10.26641/2307-0404.2020.3.214818>

A. Mackevičius¹,
V. Mosenko²,
K. Laurikėnas¹,
A. Šatavičiūtė¹,
T. Baltrūnas^{1, 2, 3},
U. Chernyaha-Royko⁴,
N. Demkova⁵,
L. Bardachenko⁶

LOW RATES OF RESTENOSIS IN PRIMARY LATERAL CAROTID ARTERY ENDARTERECTOMY

Republican Vilnius University Hospital¹

Vascular Surgery Department

Šiltnamių str., 29, Vilnius, 04130, Lithuania

Vilnius University Faculty of Medicine²

M.K. Čiurlionio str., 21, Vilnius, 03101, Lithuania

Vilnius University Hospital Santaros klinikos³

Vascular Surgery Department

Santariškių str. 2, Vilnius, 08661, Lithuania

Lviv Regional Clinical Medical and Diagnostic Cardiology Center⁴

Cardiology Department

Kul'parkivska str., 35, Lviv, 79000, Ukraine

SE «Dnipropetrovsk medical academy of Health Ministry of Ukraine»⁵

Department of Internal medicine 2 and Phthisiology

Vernadsky str., 9, Dnipro, 49044, Ukraine

CE «Dnipropetrovsk Regional Clinical Hospital named after I.I. Mechnikov» DRC⁶

ICU of Cardiology Department

Soborna sq., 14, Dnipro, 49005, Ukraine

Республіканська Вільнюська університетська лікарня¹

Відділення судинної хірургії

вул. Теплична, 29, Вільнюс, 04130, Литва

Вільнюський університет Медичний факультет²

вул. М.К. Чюрльоніса, 21, Вільнюс, 03101, Литва

Вільнюська університетська лікарня «Santaros klinikos»³

Відділення судинної хірургії

вул. Сантарішкію, 2, Вільнюс, 08661, Литва

Львівський державний обласний клінічний кардіологічний центр⁴

Відділ кардіології

вул. Кульпарківська, 35, Львів, 79000, Україна

ДЗ «Дніпропетровська медична академія МОЗ України»⁵

кафедра внутрішньої медицини 2 та фізіотерпії

вул. В. Вернадського, 9, Дніпро, 49084, Україна

КП «Дніпропетровська обласна клінічна лікарня ім. І.І. Мечникова» ДОР⁶

ПІТ Кардіологічного відділення

e-mail: valerijamosenko@gmail.com

Цитування: Медичні перспективи. 2020. Т. 25, № 3. С. 77-87

Cited: Medicni perspektivi. 2020;25(3):77-87

Key words: carotid endarterectomy, restenosis, carotid artery disease

Ключевые слова: каротидная эндартерэктомия, рестеноз, заболевание сонной артерии

Ключові слова: каротидна ендартеректомія, рестеноз, захворювання сонної артерії

Abstract. Low rates of restenosis in primary lateral carotid artery endarterectomy. Mackevičius A., Mosenko V., Laurikėnas K., Šatavičiūtė A., Baltrūnas T., Chernyaha-Royko U., Demkova N., Bardachenko L. Carotid artery endarterectomy (CAE) is a treatment of choice for symptomatic and asymptomatic high-grade carotid stenosis, showing great results in reducing stroke morbidity. The optimal technique of the arterial closure is, however, still under discussion, with both patch angioplasty and primary closure having numerous advantages and pitfalls. The definite evidence is still lacking. The aim of this study was to evaluate the results of the modified primary closure technique during CEA. Incidence of restenosis more than 8 months after the surgery was measured. A retrospective observational

study to evaluate modified primary internal carotid artery closure was conducted in Republican Vilnius University Hospital from January 1st, 2014 to December 31st, 2018. The patients were enrolled in the trial during their routine follow-up by their surgeon. During the visit, after an informed consent was signed, a qualified investigator performed carotid duplex ultrasound scan, documenting the restenosis rates. Patients also filled in the comorbidity assessment questionnaire, which included their smoking habits, history of hypertension and their adherence to antihypertensive medication as well as cholesterol levels and statin therapy, additional related comorbidities. Out of 342 patients that underwent CAE with primary closure in the Republican Vilnius university hospital from 2014 to 2018, 42 patients were identified as deceased, therefore a follow-up was impossible. Out of planned 150 (50%) consequently selected patients, 125 gave an informed consent to be enrolled into the study. Out of those 6 pre-occlusions were established during the review of the patient medical data and therefore were excluded from the study. In general, we analyzed the data of 119 patients and 125 CAE with a modified primary suture closure. The mean follow-up time was 35.78 months (SE 0.992; SD 11,046). At the time of a follow up, 3 (2,4%) carotid artery occlusions were identified and promptly evaluated. Restenosis rates varied: 5,6% of patients had low grade (<50%), 5,6% had moderate grade (50-69%) and 1,6% had high grade (70-99%) stenosis. The modified lateral CAE with primary closure technique, used in our hospital's contemporary practice has shown to be a promising alternative to the classical primary suture, due to reduced restenosis rates. More prospective and randomized studies are needed to evaluate this technique in comparison to other CAE closure techniques.

Реферат. Низькі рівні рестенозу при первинній латеральній ендартеректомії. Мацкявичус А., Мосенко В., Лаурикенас К., Шатавичуте А., Балтрунас Т., Чернях-Ройко У., Демкова Н., Бардаченко Л. Ендартеректомія сонної артерії (ЕСА) – це лікування, яке вибирається для симптоматичного та безсимптомного високо-стероїдного стенозу сонної артерії, показуючи відмінні результати у зменшенні захворюваності на інсульт. Однак оптимальна техніка закриття артерій все ще обговорюється, оскільки як ангіопластика, так і первинне закриття мають численні переваги та підводні камені. Певних доказів досі бракує. Метою цього дослідження була оцінка результатів модифікованої методики первинного закриття під час ЕСА. Частота рестенозу була виміряна понад 8 місяців після операції. Ретроспективне спостережне дослідження для оцінки модифікованого первинного закриття сонної артерії було проведено в Республіканській лікарні Вільнюського університету з 1 січня 2014 року по 31 грудня 2018 року. Пацієнти були включені в дослідження під час планового спостереження хірургом. Під час візиту, після підписання інформованої згоди, кваліфікований дослідник зробив дуплексне ультразвукове дослідження сонної артерії, задокументувавши рівень рестенозу. Пацієнти також заповнили опитувальник з оцінки супутньої патології, який включав їх звички куріння, артеріальну гіпертензію в анамнезі та їх прихильність до антигіпертензивних препаратів, а також рівень холестерину та терапію статинами, додаткові супутні захворювання. З 342 пацієнтів, які пройшли ЕСА з первинним закриттям у Республіканській університетській лікарні Вільнюса з 2014 по 2018 рік, 42 пацієнти були визнані померлими, тому не змогли з'явитися для подальшого спостереження. Із запланованих 150 (50%), відповідно обраних пацієнтів, 125 дали інформовану згоду на участь у дослідженні. Серед них 6 близьких оклюзій було встановлено під час перегляду медичних картотек пацієнта і тому виключено з дослідження. Загалом ми проаналізували дані 119 пацієнтів та 125 ЕСА із модифікованим первинним закриттям швів. Середній час спостереження становив 35,78 місяця (СП 0,992; СВ 11046). На момент подальшого спостереження було виявлено та негайно оцінено 3 (2,4%) оклюзії сонної артерії. Частота рестенозу варіювала: 5,6% пацієнтів мали низький ступінь (<50%), 5,6% мали середній ступінь (50-69%) та 1,6% мали високий ступінь (70-99%) стенозу. Модифікований латеральний ЕСА з первинною методикою закриття, який використовується в сучасній практиці нашої лікарні, виявився перспективною альтернативою класичному первинному шву через зниження рівня рестенозу. Для оцінки цієї методики потрібні більші проспективні та рандомізовані дослідження у порівнянні з іншими методами закриття ЕСА.

Carotid endarterectomy (CEA) is a proven intervention for preventing and reducing the risk of stroke in patients with both symptomatic and asymptomatic carotid artery stenosis [1]. This surgical technique is durable and effective with low rates of morbidity and mortality[1], comparing to carotid artery stenting (CAS) and best medical therapy (BMT). It is, however, associated with restenosis rates averaging at 5.8% according to the most recent systematic review by Batchelder et al. [2]. Despite the significant efficacy and popularity of CEA, there is still a significant ongoing debate regarding the best method of artery closure, with

numerous RCTs and systematic analyses favoring different revascularization techniques. Numerous retrospective studies, comparing primary closure of the carotid artery versus patch angioplasty outcomes, have been published. Several of the analyses have suggested that a patch angioplasty as an effective way of preventing acute internal carotid artery thrombosis due to increasing vascular lumen width, reducing the risk of perioperative stroke and is associated with the patch angioplasty with a lower risk of restenosis [3, 4]. However other studies have shown that there is no difference in the rate of restenosis after CEA with a primary closure and

patch angioplasty [5]. Accepted indications for patch angioplasty after CEA traditionally include a very small internal carotid artery (<4 mm), an extended, complex, or irregular arteriotomy, and concomitant repair of a distal internal carotid artery that contains a kink or coil [1]. Patching may allow optimization of blood flow, vessel geometry, and biomechanics, although the influence of these physical parameters on long-term patient outcome is not well described. Possible disadvantages of patch closure are longer carotid clamping time and possible complications associated with vein harvesting [5] as well as association with such rare but dangerous complications as patch rupture and formation of both false and proper carotid aneurysm [5]. One of the most notable findings was the association of saphenous vein use with an increased patch rupture risk [6, 7]. In 2010 a Rerkasem et al Cochrane review suggested that the vein patches may rupture more easily with potentially fatal consequences and synthetic materials are more vulnerable to infection [7]. Another popular option as a biomaterial patch for CEA is the Bovine pericardium. When compared with outcomes of polyester patches, bovine pericardial patches show comparable results but may have a lower incidence of recurrent stenosis. Although no reports have compared bovine pericardium with other conduits regarding rates of postoperative infection, bovine pericardium has been used in other infected cardiovascular fields [8]. Considering all the controversial reviews and the lack of the objective comparable data on the patch material of choice, CEA with primary closure and adequate medical therapy may be equally effective at preventing recurrent stenosis and has the advantage of reduced operative time [5]. The overall evidence is limited and contradictory and is mostly based on the experience of the center the trial was conducted in. The meta-analyses and systematic reviews of the last decade mostly highlight the decreased incidence of perioperative strokes using patch angioplasty technique. The clinical significance of the rate of restenosis, however is still questionable, especially in terms of long-term stroke prevention [5]. The contemporary practice for CAE with primary closure in The Republican Vilnius University Hospital is to use an alternative closure technique, which is presented below (Fig. 1-6.) The aim of this paper is to evaluate the results of the modified closure technique in regard to both restenosis rates and cross-clamping time as well as compare them to published CAE and CAS results.

MATERIALS AND METHODS OF RESEARCH

The study protocol and an informed consent form were approved by Republican Vilnius university

hospital bioethics board as well as Vilnius Regional Biomedical Research Ethics Committee. This study was a retrospective analysis [9] of the long-term results of patients who underwent CEA with modified primary closure between the years 2014 and 2018 in the Republican Vilnius university hospital in Lithuania. All the patients selected for the carotid endarterectomy, both symptomatic and asymptomatic, had the stenosis of the affected ICA greater than 70% (high grade stenosis – according to NASCET criteria [1]), confirmed during either a Duplex ultrasound or carotid angiography according to European guidelines [1].

Data collection

Inclusion criteria

- Patients who had CAE with modified primary suture performed in Republican Vilnius University Hospital from 2014 to 2018.

- Patients, who at the time of surgery were 41-99 years of age.

- Patients that gave their informed consent to be a part of the study.

Exclusion criteria

- Patients with carotid near occlusion (>99%), established intraoperatively.

- Patients whose carotid artery stenosis was not of the atherosclerotic origin.

- Patients whose surgery was performed with a different arteriotomy closure technique.

- Patients that did not give consent for their health data usage in this trial.

The patients were randomly enrolled into the trial during their routine follow-up by their surgeon. During the visit, if given an informed consent, a qualified investigator performed carotid duplex US scan, documenting the stenosis and restenosis rates using the duplex scan protocol assessing PSV (peak-systolic velocity) and EDV (end-diastolic velocity) in common and internal carotid arteries. To standardize and categorize the findings, restenosis was classified into 3 groups, based on the NASCET criteria: mild, <50% (ICA/CCA PSV, 0.1-1.9; PSV <125; EDV <40); moderate, 50% to 69% (ICA/CCA PSV, 2.0-4.0; EDV >40); and severe, 70% to 99% (ICA/CCA PSV >4; PSV >230; EDV >40). Patients were also asked to answer the comorbidity assessment questions, which included their smoking habits, history of hypertension and their adherence to antihypertensive medication as well as cholesterol levels and statin therapy, additional related comorbidities were recorded as well.

Operative technique

All the surgeries were performed under general anesthesia. According to hospital protocol, all patients received 5000 units of heparin IV before

clamping of the internal carotid artery as well as induced hypertension to a systolic pressure more than 160 mmHg or at least 25% more than baseline level was used. The artery was then occluded, the patients' response was observed with intracranial doppler (ICD). Patients received selective shunting if changes on the ICD post-clamping were found.

Lateral arteriotomy (Fig. 1), avoiding glomus caroticum, was done. Careful endarterectomy was performed with Penfield dissector and the artery was closed with 6-0 Prolene, using microsurgical technique. Postoperatively patients were hospitalized in the intensive care unit overnight.

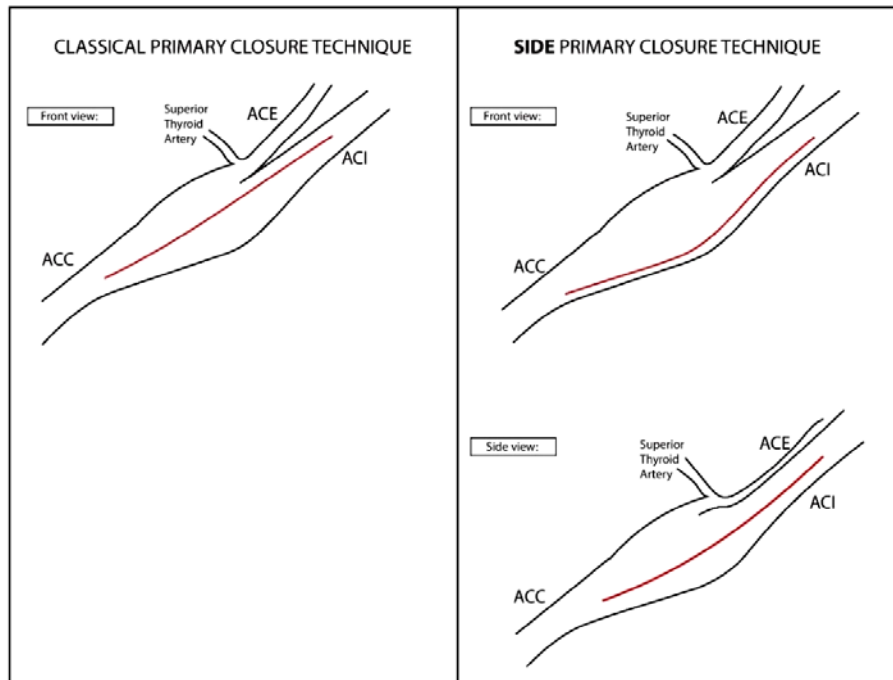


Fig. 1. Classical (left) vs lateral (right) primary closure technique

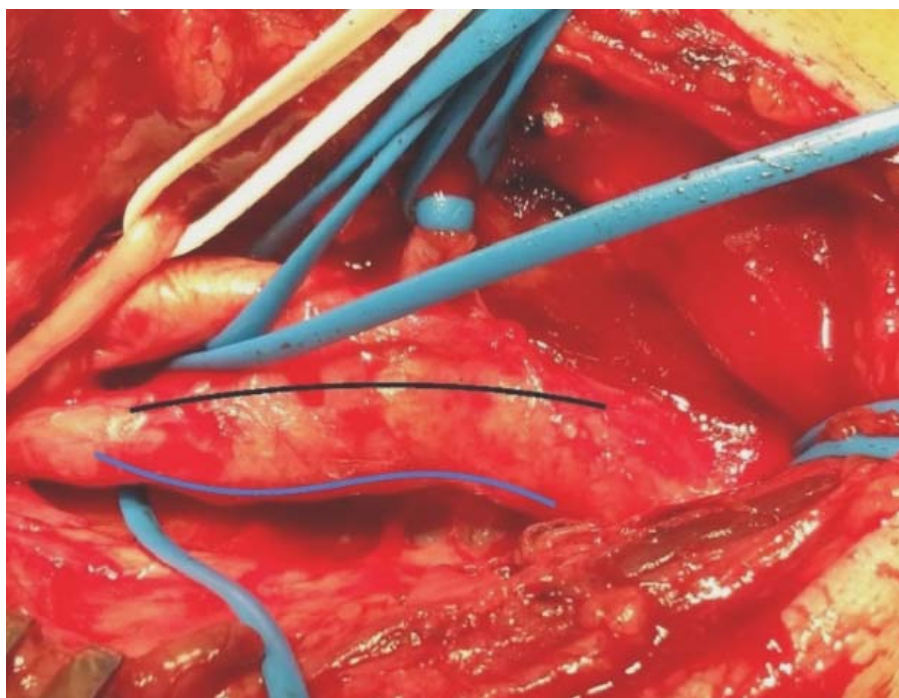


Fig. 2. Endarterectomy with lateral (blue) vs classical (black) primary closure technique intraoperatively

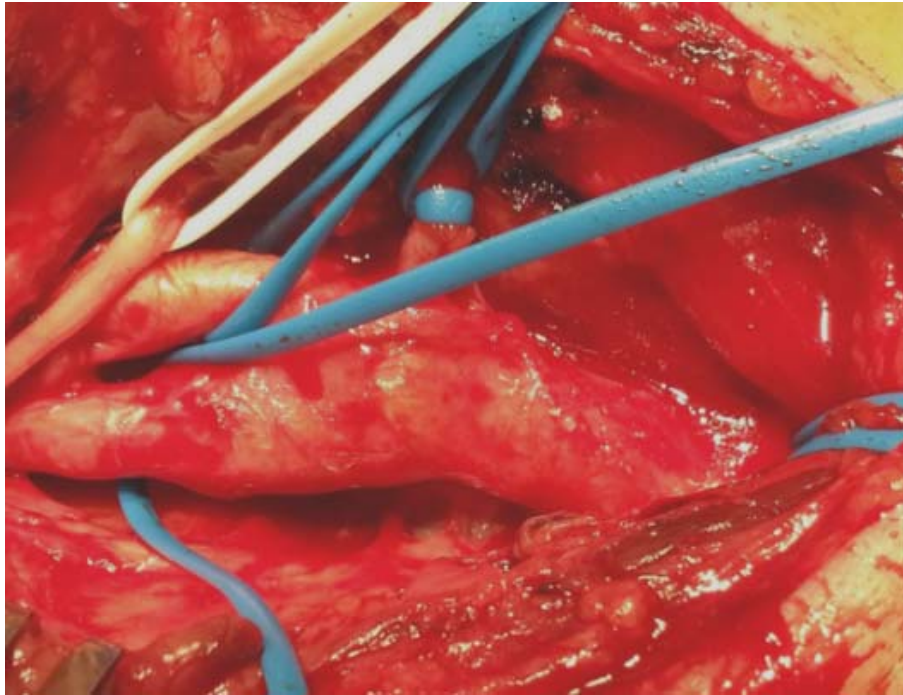

Fig. 3. Carotid artery exposure

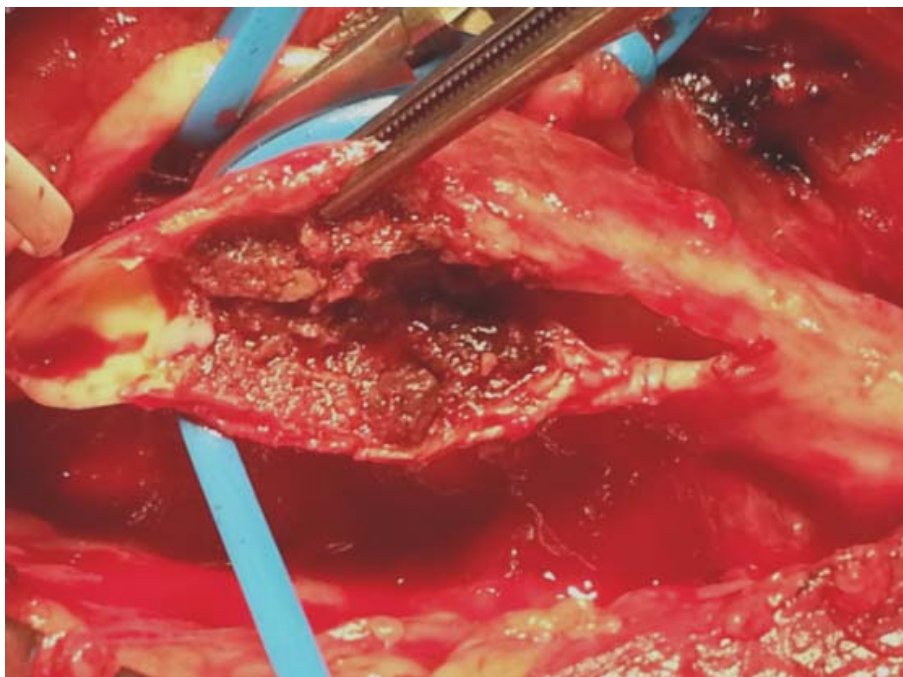


Fig 4. Lateral arteriotomy and atherosclerotic plaque exposure

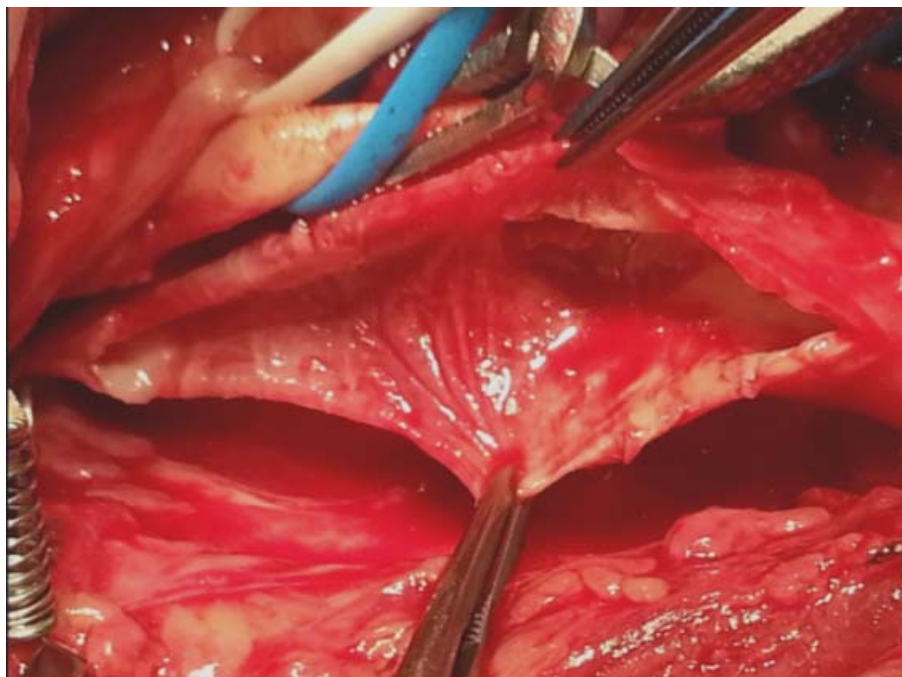


Fig. 5. Carotid artery after the endarterectomy

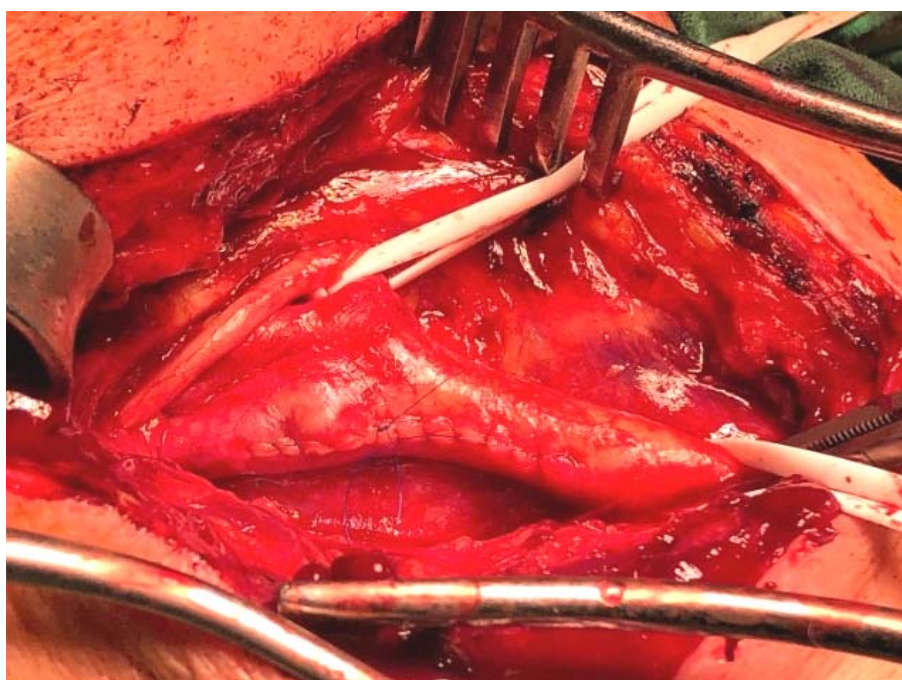

Fig. 6. Modified lateral suture

Follow-up.

The mean follow-up time was 35.78 months (S.E. 0.992; SD 11,046), ranging from 8 to 55 months after the surgery.

Statistical analysis.

Statistical analyses were performed with IBM SPSS for Windows Version 23.00 (Individual usage

license 4-2CE07) Numeric variables were expressed as mean \pm standard deviation and median (min-max); categorical variables were expressed as number and percentage. Outcomes were assessed using Kaplan-Meier life [10] table analysis. Univariate analysis of variables potentially associated with study endpoints was performed, and

those that were statistically significant (threshold of 0.05) were included in a multiple logistic regression [11] in order to identify predictors of the restenosis.

Demographics and clinical features.

Out of 342 patients that underwent CAE with primary closure in the Republican Vilnius university hospital from 2014 to 2018, 42 (12.28%) patients were indentified as deceased (40 from unrelated causes, 2 from postoperative complications), therefore a follow-up was impossible. The goal was to enroll 50% (N=150) of the modified CAE patients, however only 125 (83.3%) out of randomly selected 150 patients gave an informed consent to be enrolled into the study. Out of those 6 pre-occlusions were established during the review of the patient's medical files and therefore excluded from the study. In general, we analyzed the data of 119 patients and 125 CAE with primary suture surgeries. Six patients

underwent bilateral procedures with 1 or 2 months break in-between. The study population consisted of 62.7% men and 37.3% women. 57 (47.9%) of observed patients were symptomatic and 62 (52.1%) were asymptomatic. The average age was 70.14 years and the age range was 42 to 90 years. Many patients had comorbidities including tobacco abuse (42.4% before CAE, 18.6% after CAE), hyperlipidemia (46.6%), cardiovascular disease (24.4%), myocardial infarction or coronary heart disease (6.7%), documented hypertension (6.7%) diabetes (5%). 57 patients (47.9%) were treated for a symptomatic carotid stenosis. 47 (82.5%) of symptomatic patients had a history of stroke, 13 (22.8%) had TIA and 3 (5.3%) had amaurosis fugax. 62 (52.1%) patients were asymptomatic. Baseline population characteristics are presented in table 1.

Table 1

Baseline characteristics

Variable	N=119	Symptomatic (n=57)	Asymptomatic (n=62)
Age, mean (SD)	70.14 (9)	69.77 (8.26)	70.48 (9.68)
Male sex (%)	74 (62.7%)	35 (62.5%)	39 (62.9%)
Symptomatic (%)	57 (47.9%)		
Smoking (before CAE) (%)	50 (42.4%)	24 (42.9%)	26 (41.9%)
Smoking (after CAE) (%)	22 (18.6%)	11 (19.6%)	11 (17.7%)
Hyperlipidemia (%)	55 (46.6%)	27 (48.2%)	28 (45.2%)
Statin use (%)	58 (49.2%)	29 (50.9%)	29 (46.8%)
Diabetes (%)	6 (5%)	4 (7%)	2 (3.2%)
Stroke (before CAE) (%)	63 (52.9%)	47 (82.5%)	16 (25.8%)*
TIA (before CAE) (%)	43 (36.1%)	13 (22.8%)	30 (48.4%)*
Amaurosis fugax (%)	3 (2.5%)	3 (5.3%)	0 (0%)
CVD (%)	29 (24.4%)	18 (31.6%)	11 (17.7%)
PAH (%)	8 (6.7%)	5 (8.8%)	3 (4.8%)
High BP (after CAE) (%)	99(85.3%)	48 (85.7%)	51 (85.0%)
BP management (after CAE) (%)	90 (77.6%)	46 (83.6%)	44 (72.1%)
MI and/or CHD (%)	8 (6.7%)	6 (10.5%)	2 (3.2%)

Note: BP – blood pressure; TIA – transient ischemic attack; CVD – cardiovascular disease, MI – myocardial infarction, CHD – coronary heart disease, PAH – primary arterial hypertension; CAE – carotid artery endarterectomy. *The strokes and TIA included in the asymptomatic group are not of affected carotid origin.

Restenosis rates.

At the time of a follow up, out of 119 patients (125 endarterectomies) included, 3 (2.4%) carotid artery occlusions were identified and promptly evaluated. Restenosis rates varied: 15.2% of the arteries had any grade of restenosis, 5.6% of the patients had low grade (<50%) (low grade restenosis can be only evaluated on the Duplex US and usually not seen on both CTA and DSA), 5.6% had moderate grade (50-69%) and 1.6% had high grade

(70-99%) stenosis. All in all, clinically relevant [1], meaning occlusion or high-grade, restenosis frequency added up to 4% at the time of a follow up. The occlusions were identified in 35, 40 and 51 months after CAE, while the high-grade restenosis (70-99%) were noted in 41 months post-surgery, therefore we can hypothesize that all found occlusions and high-grade (70-99%) restenoses may be a *de-novo* atherosclerotic process.

Table 2

After internal carotid artery (ICA) endartrectomy at the time of a follow up

Restenosis	Frequency	Valid Percent
Occlusions	3	2,4
<50%	7	5,6
50-69%	7	5,6
70-99%	2	1,6
No restenosis	106	84,8
Total	125	100,0

Table 3 illustrates that the median for any grade restenosis is 53 months, meaning 50% of patients will not develop any grade restenosis in 53 months.

All of the included patients were asymptomatic during follow up, therefore the main focus of the investigation was high grade (70-99%) restenosis, which might warrant a reintervention [1].

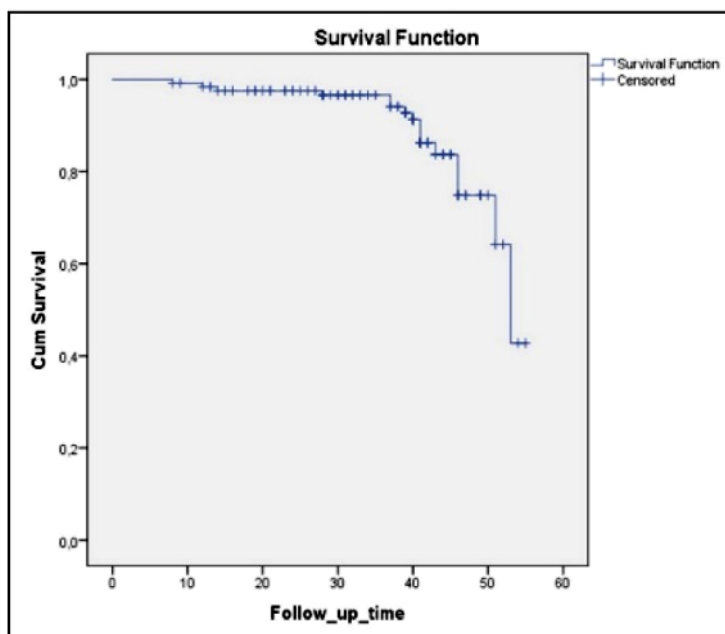


Fig. 7. Any grade restenosis or occlusion after endarterectomy

Table 3

Means and medians for any grade of restenosis time

Mean ^a				Median			
Estimate	Std. Error	95% Confidence Interval		Estimate	Std. Error	95% Confidence Interval	
		Lower Bound	Upper Bound			Lower Bound	Upper Bound
50.125	1.051	48.065	52.185	53.000	1.788	49.496	56.504

Note. a. Estimation is limited to the largest survival time if it is censored

RESULTS AND DISCUSSION

No discussion on the optimal revascularization technique is complete without one of the most widely discussed complications after carotid interventions – restenosis, which was the focal point of our research as it is usually under reported and mostly theoretically speculated, especially in the

case of carotid endarterectomy with primary suture. Our center set the task to clear up how our modified primary suture restenosis rates are comparable to those of the classical CAE with primary suture techniques.

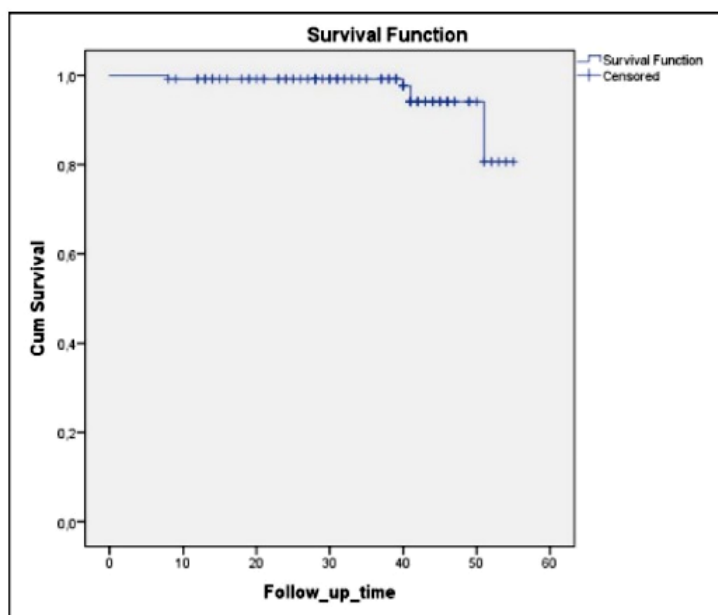


Fig. 8. High grade restenosis or occlusion after carotid endarterectomy

Restenosis are more likely to develop in the first 6-12 months after CEA and are usually due to neointimal hyperplasia [12]. Lesions developing after 24-36 months are usually related to the recurrence of the atherosclerotic process [14]. The reported restenosis rates (>50%) for the CAE with primary suture vary from 6 to 14% [1]. Brothers et al reported rates of >50% restenosis as 38% and 6% (p<0.001) for eversion and patch CEA in 36 months by life table analysis [13]. Reinert et al study of 586

patients after CAE with primary closure, reported high-grade (>70%) restenosis rate in 1 year as 3.2% [12].

This compares favorably to our results, as we report that the use of the modified lateral primary closure for CAE leads to fewer restenosis rates, adding up to 7,2% for a moderate to high grade stenosis, 2,4% for occlusions and 1,6% for high-grade stenosis, which may warrant the need for reintervention. The median time of no-clinically-relevant-restenosis was, unfortunately, impossible to

calculate, as there was not enough events to produce a statistically relevant prediction using Kaplan-Meier survival curve. However, the Kaplan-Meier Survival curve analysis results raise a few questions regarding the results of the modified CAE technique. The most important question to ask is whether there is a reason in the sharp drop in 50 months of follow-up? Two hypotheses can be posed. Either there is some type of underlying or de novo pathology manifesting in about 4 years after the surgery that causes a high-grade restenosis or earlier (approximately 2014) surgeries may have been a part of the insufficient learning and therefore their outcomes are worse than the later ones. There is not enough information in this study to prove or disprove any of the two, therefore it may be an additional direction of the research for further publications.

Another advantage of the described technique is that the cross-clamping time of the carotid artery was considerably reduced. According to the medical files data from this study, the mean cross-clamping time was 32±12 minutes. Comparison of this time to

the one found in the published literature is favorable, for example Ucci et al study outlined the cross clamping time of their study as 48±13.5 minutes [14] and Arzu Antal et al as 59.95±24.72 minutes [15].

CONCLUSION

The modified lateral CAE with primary closure technique, used in our hospital's contemporary practice has shown to be a great alternative to the classical primary suture for CAE technique in regards to reduced restenosis rates as well as considerably shortened cross-clamping of the carotid artery, which in turn reduces the risk of ischemic brain injury. However more prospective and randomized studies are needed to evaluate this technique in comparison to other CAE closure techniques.

Conflict of interests. The authors declare no conflict of interest.

Funding information. This research and none of its authors received no specific grant from any funding agency in the public, commercial, or not-for-profit sectors.

REFERENCES

1. Editor's Choice – Management of Atherosclerotic Carotid and Vertebral Artery Disease: 2017 Clinical Practice Guidelines of the European Society for Vascular Surgery (ESVS) – European Journal of Vascular and Endovascular Surgery [Internet]. [cited 2019 Nov 13]. doi: <https://doi.org/10.1016/j.ejvs.2017.06.021>
2. Batchelder A, Saratzis A, Naylor AR. Editor's Choice – Overview of Primary and Secondary Analyses From 20 Randomised Controlled Trials Comparing Carotid Artery Stenting With Carotid Endarterectomy – PubMed. *Eur J Vasc Endovasc Surg.* 2019 Oct;58(4):479-93. doi: <https://doi.org/10.1016/j.ejvs.2019.06.003>
3. Goodney PP, Nolan BW, Eldrup-Jorgensen J, Likosky DS, Cronenwett JL, Vascular Study Group of Northern New England. Restenosis after carotid endarterectomy in a multicenter regional registry. *J Vasc Surg.* 2010 Oct;52(4):897-904:905. doi: <https://doi.org/10.1016/j.jvs.2010.05.005>
4. Bonati LH, Gregson J, Dobson J, McCabe DJH, Nederkoorn PJ, van der Worp HB, et al. Restenosis and risk of stroke after stenting or endarterectomy for symptomatic carotid stenosis in the International Carotid Stenting Study (ICSS): secondary analysis of a randomised trial. *Lancet Neurol.* 2018 Jul;17(7):587-96. doi: [https://doi.org/10.1016/S1474-4422\(18\)30195-9](https://doi.org/10.1016/S1474-4422(18)30195-9)
5. Mertens V, Maertens H, Kint M, Coucke C, Blomme Y. Complication Rate after Carotid Endarterectomy Comparing Patch Angioplasty and Primary Closure. *Ann Vasc Surg.* 2016 Jan;30:248-52. doi: <https://doi.org/10.1016/j.avsg.2015.07.045>
6. Edenfield L, Blazick E, Eldrup-Jorgensen J, Healey C, Bloch P, Hawkins R, et al. Outcomes of carotid endarterectomy in the Vascular Quality Initiative based on patch type. *J Vasc Surg.* 2019 Sep 3. doi: <https://doi.org/10.1016/j.jvs.2019.05.063>
7. Rerkasem K, Rothwell PM. Patches of different types for carotid patch angioplasty. *Cochrane Database Syst Rev.* [Internet]. 2010;3. [cited 2019 Dec 1]. doi: <https://doi.org/10.1002/14651858.CD000071.pub2>
8. Huizing E, Vos CG, van den Akker PJ, Schreive MA, de Borst GJ, Ünlü Ç. A systematic review of patch angioplasty versus primary closure for carotid endarterectomy. *J Vasc Surg.* 2019 Jun;69(6):1962-74.e4. doi: <https://doi.org/10.1016/j.jvs.2018.10.096>
9. Perry JD, Parrish RK, Goodman KW. The Prospective Retrospective Study. *Am J Ophthalmol.* 2018;196:xiii–xv. doi: <https://doi.org/10.1016/j.ajo.2018.09.006>
10. Jager KJ, van Dijk PC, Zoccali C, Dekker FW. The analysis of survival data: the Kaplan-Meier method. *Kidney Int.* 2008 Sep;74(5):560-5. doi: <https://doi.org/10.1038/ki.2008.217>
11. Sperandei S. Understanding logistic regression analysis. *Biochem Medica.* 2014 Feb 15;24(1):12-8. doi: <https://doi.org/10.11613/BM.2014.003>
12. Kumar R, Batchelder A, Saratzis A, Abu-Rahma AF, Ringleb P, Lal BK, et al. Restenosis after Carotid Interventions and Its Relationship with Recurrent Ipsilateral Stroke: A Systematic Review and Meta-analysis. *Eur J Vasc Endovasc Surg.* 2017 Jun 1;53(6):766-75. doi: <https://doi.org/10.1016/j.ejvs.2017.02.016>
13. Brothers TE. Eversion carotid endarterectomy: Higher recurrent or residual stenosis rates within 36 months are not related to a short learning curve. *J Vasc Surg.* 2005;42:429-34. doi: <https://doi.org/10.1016/j.jvs.2005.05.017>

14. Alessandro Ucci, et al. One-year experience in carotid endarterectomy combining general anaesthesia with preserved consciousness and sequential carotid cross-clamping. *Acta Bio-Medica Atenei Parm.* 2018 Mar 27;89(1):61-6. doi: <https://doi.org/10.23750/abm.v89i1.6814>

15. Dönmez AA, Adademir T, Sacli H, Koksal C, et al. Comparison of Early Outcomes with Three Approaches for Combined Coronary Revascularization and Carotid Endarterectomy. *Braz J Cardiovasc Surg.* 2016 Oct;31(5):365-70. doi: <https://doi.org/10.5935/1678-9741.20160076>

Стаття надійшла до редакції
06.04.2020

