

G.P. Kuzmina*,
O.Ya. Markova,
O.M. Lazarenko

CLINICAL CASE OF SEVERE VISCERAL COMPLICATIONS WITH ATYPICAL LOCALIZATION IN A PATIENT WITH GOUT

Dnipro State Medical University

30-ty richchia Peremohy sq., 2, Kryvyi Rih, Dnipropetrovsk region, 50056, Ukraine

Дніпровський державний медичний університет

майд. 30-річчя Перемоги, 2, Кривий Ріг, Дніпропетровська область, 50056, Україна

*e-mail: revmatologymedd@gmail.com

Цитування: Медичні перспективи. 2023. Т. 28, № 1. С. 208-216

Cited: Medicni perspektivi. 2023;28(1):208-216

Key words: gout, blood uric acid, monosodium urate crystals

Ключові слова: подагра, сечова кислота крові, кристали моноурату натрію

Abstract. Clinical case of severe visceral complications with atypical localization in a patient with gout.

Kuzmina G.P., Markova O.Ya., Lazarenko O.M. The diagnosed gout is a signal to search for unrecognized concomitant conditions and their underlying causes and mechanisms of development. Due to the fact that gout is a common metabolic disorder with symptoms of localized inflammation caused by chronic and/or episodic deposition of monosodium urate crystals (MSU) in joints and soft tissues, the understanding of the inflammation interaction in metabolic disorders has changed. In cases of severe visceral complications of gout, the most common sites of tophl are kidneys, liver, spleen, lungs, pericardium, subcutaneous tissue and other soft tissues. The aim of this study was to outline the features of severe visceral complications with atypical localization in a patient with gout (identification of MSU crystals with polarization microscopy) and to determine the role of videothoracoscopy in this case. Patient N., 55 years old, complained of moderate chest pain, shortness of breath during exercise, general weakness and occasional cough. The patient was hospitalized in a multidisciplinary clinical institution. Examinations were performed, including polarization microscopy, spiral computed tomography (polytopic foci, formations), videothoracoscopy. Endoscopic resection of SVII of the lower lobe of the left lung with a biopsy of the lungs formations and mediastinal lymph nodes was performed. Results of histologic examination: amorphous masses are presented in combination with the organized chronic giant cell granulomatous structure (tophus), which contains clusters of crystals of MSU. Cytological examination of pleural cavity fluid revealed the presence of crystals of MSU. The presence of crystals of MSU was confirmed by polarization microscopy. From the anamnesis of the disease it became known that at the age of 38 the patient consulted a rheumatologist for moderate joint syndrome. On the basis of anamnesis, laboratory and instrumental data (X-ray, ultrasound examination) the diagnosis of gout, chronic gouty arthritis was established. Urate lowering therapy was prescribed. The patient took the drugs periodically without re-consultation with the doctor. The presented case of untreated gout has led to significant structural disorders in organs such as lungs, pleura. Endoscopic resection of the lower lobe of the left lung and revision of the thoracic cavity revealed atelectasis, hemorrhage, inflammatory infiltration, fibrous changes in tissues, amorphous masses with organized chronic giant cell granulomatous structure, presented by crystals of MSU. During the surgery, a powdery substance was found on the pleura surfaces. A video thoracoscopy in this case was a means to present a visceral damage in gout. The search for diagnostic tools to diagnose a severe visceral complications with atypical localization in gout still remains unsolved. Undoubtedly, the central role in the development of gout is played by the deposition of numerous crystals of MSU. In the patient under observation, crystals of MSU were found in pleural fluid and sputum consisting of sodium urate, like the known facts of their appearance in the joint fluid and urine. Uric acid salt crystals were also detected in the areas of pulmonary fibrosis formation according to the results of radiological examination, as well as endoscopic intervention in the lower lobe of the left lung.

Реферат. Клінічний випадок тяжких вісцеральних ускладнень з атиповою локалізацією в пацієнтки з подагрою. Кузьміна Г.П., Маркова О.Я., Лазаренко О.М. Діагноз подагри – це сигнал до пошуку нерозпізнаних супутніх станів і причин, що їх викликають, та механізмів розвитку. З огляду на те, що подагра представляє собою поширене порушення обміну речовин із симптомами локалізованого запалення, яке викликається хронічним і/або епізодичним відкладанням кристалів моноурату натрію (МУН) у суглобах і м'яких тканинах, змінилося розуміння щодо взаємодії запалення при метаболічних порушеннях. У випадках тяжких вісцеральних ускладнень при подагрі найбільш частими місцями відкладення тофусів є нирки, печінка, селезінка, легені, перикард, підшкірні тканини та інші м'які тканини. Метою цього дослідження було окреслити особливості тяжких вісцеральних ускладнень з атиповою локалізацією в пацієнтки з подагрою (ідентифікація кристалів МУН з проведенням поляризаційної мікроскопії) та визначення ролі відеоторакоскопії в наведеному випадку.

Пацієнтка Н., 55 років, звернулася зі скаргами на помірно виражений біль у грудях, задихку при фізичному навантаженні, загальну слабкість та періодичний кашель. Пацієнтку госпіталізовано до багатопрофільної клінічної установи. Проведено обстеження, у тому числі поляризаційну мікроскопію, спіральну комп'ютерну томографію (виявлено політопні вогнища, утворення), відеоторакокопію. Проведена ендоскопічна резекція SVII нижньої частки лівої легені з наступною біопсією утворень легень і лімфовузлів середостіння. Результати гістологічного дослідження: аморфні маси представлені в сполученні з організованою хронічною гігантоклітинною гранулематозною структурою (тофус), яка містить скупчення кристалів МУН. Цитологічне дослідження рідини плевральної порожнини встановило наявність кристалів МУН. Методом поляризаційної мікроскопії підтверджено наявність кристалів МУН. З анамнезу хвороби стало відомо, що у віці 38 років пацієнтка зверталася до ревматолога з помірно вираженим суглобовим синдромом. На основі анамнезу, лабораторних та інструментальних даних (рентгенологічне, ультразвукове дослідження) був встановлений діагноз подагри, хронічного подагричного артриту. Призначено уратзнижувальну терапію. Пацієнтка приймала препарати періодично без повторної консультації з лікарем. Представлений випадок нелікованої подагри призвів до вагомих структурних порушень у таких органах, як легені, плевра. Ендоскопічна резекція нижньої частки легені зліва і ревізія грудної порожнини виявили ателектаз, крововилив, запальну інфільтрацію, фіброзно змінені тканини, аморфні маси з організованою хронічною гігантоклітинною гранулематозною структурою, яка представлена кристалами МУН. Під час оперативного втручання на поверхні плеври виявлено порошкоподібну речовину. Відеоторакокопія в цьому випадку виявилася засобом представлення вісцерального пошкодження при подагрі. Пошук діагностичних засобів щодо діагностики тяжких вісцеральних ускладнень з атиповою локалізацією при подагрі досі залишається невирішеним. Безумовно, центральну роль у розвитку подагри відіграє відкладення безлічі кристалів МУН. У пацієнтки, яку ми спостерігали, кристали МУН виявлені в рідині плевральної порожнини, мокротинні, подібно до відомих фактів їх появи в суглобовій рідині та сечі. Кристали сечової кислоти були також виявлені в ділянках формування фіброзу легень за результатами променевого дослідження, а також ендоскопічного втручання в ділянці нижньої частки лівої легені.

The diagnosed gout is a signal to search for unrecognized concomitant conditions and their underlying causes and mechanisms of development [1]. Due to the fact that gout is a common metabolic disorder with symptoms of localized inflammation caused by chronic and/or episodic deposition of monosodium urate crystals (MSU) in joints and soft tissues, the understanding of the inflammation interaction in metabolic disorders has changed [2]. Hyperuricemia is defined as serum uric acid (UA) >6.0 mg/dL in women and >7.0 mg/dL in men and is an independent risk factor with a strong non-linear concentration that depends on the incidence of gout [3]. Genetically identified variants of 43 genes related to hyperuricemia contribute to the development of more severe forms of gout. In case of stable elevated UA levels (over 6 mg/dL) in patients with hypertension, hyperlipidemia, etc., despite adequate correction of acute gout episodes, there are other problematic issues that require screening and aggressive treatment for high levels of serum UA [4]. It is generally accepted that other risk factors should be identified in patients with elevated serum UA levels (over 6 mg/dL). A number of scientists have outlined the link between hyperuricemia and other related events, which is gaining biological significance [5]. Among patients with hyperuricemia, only in 36% there develop a gout and not all patients with gout suffer from hyperuricemia. Almost 70% of patients with asymptomatic hyperuricemia could not notice the deposition of MSU crystals. This discrepancy has contributed to a great deal of scientific controversy about the role of MSU in gout [6]. Therefore, today

the search for additional factors influencing the risk of gout continues. Additional factors such as anemia, atrial fibrillation, obstructive sleep apnea, osteoporosis, venous thromboembolism, and erectile dysfunction come into play. A weak correlation between gout and hyperuricemia has been proven. The typical progression of gout is characterized by various conditions, including hyperuricemia without MSU crystal deposition, MSU crystal deposition without symptomatic gout, acute gout attacks, chronic gouty and tophus arthritis [7]. In our opinion, the above additional factors combine pathogenetic mechanisms, including the formation of chemotactic cytokines, cell proliferation and inflammation, as well as combined proapoptotic and inflammatory effects under the influence of MSU [8]. In cases of severe visceral complications of gout, the most common sites of gouty pearls are kidneys, liver, spleen, lungs, pericardium, subcutaneous tissue and other soft tissues [9].

The aim of this study was to outline the features of severe visceral complications with atypical localization in a patient with gout (identification of MSU crystals with polarization microscopy) and to determine the role of videothoracoscopy in this case.

In this article we present a clinical case of a patient from Ukraine with severe visceral complications with atypical localization in gout. The patient's consent to publish the data was obtained.

The research was conducted in accordance with the principles of bioethics set out in the WMA Declaration of Helsinki – “Ethical principles for medical research involving human subjects” and “Universal Declaration on Bioethics and Human Rights” (UNESCO).

Clinical case

Patient N., 55 years old, complained of moderate two-week chest pain, shortness of breath during exercise, general weakness and occasional cough.

The patient was hospitalized in a multidisciplinary clinical institution (16 November 2021). Studies (clinical, biochemical including troponin, electrocardiographic, echocardiography, vascular ultrasound)

have ruled out acute myocardial infarction, thrombosis in the ear, aneurysm and lesions of the valvular heart. Given the limitations of movements in the torso, the ineffectiveness of analgesics on the background of preserved lung function with suspicion of a tumor process of the thoracic cavity, spiral computed tomography (CT) was performed (Fig. 1).

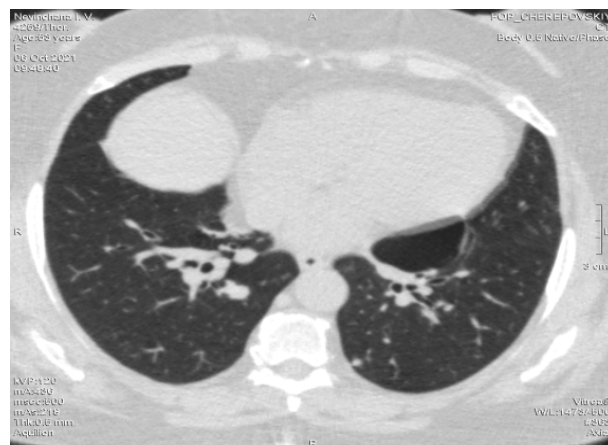
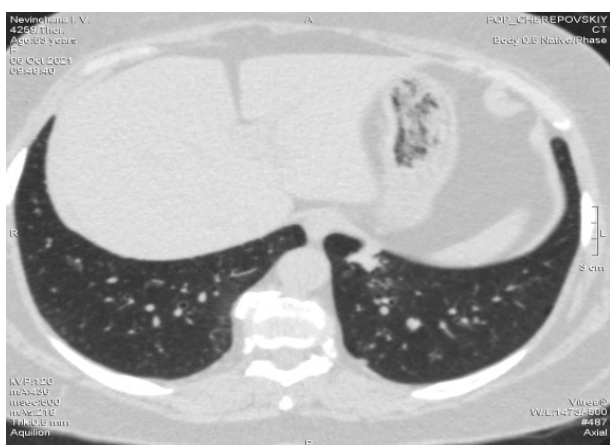

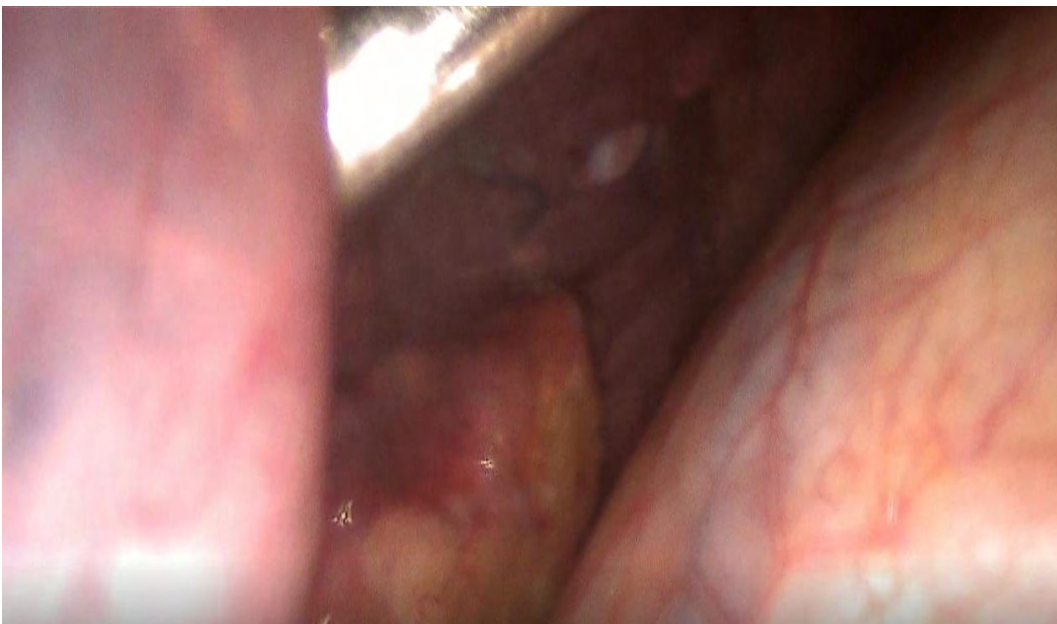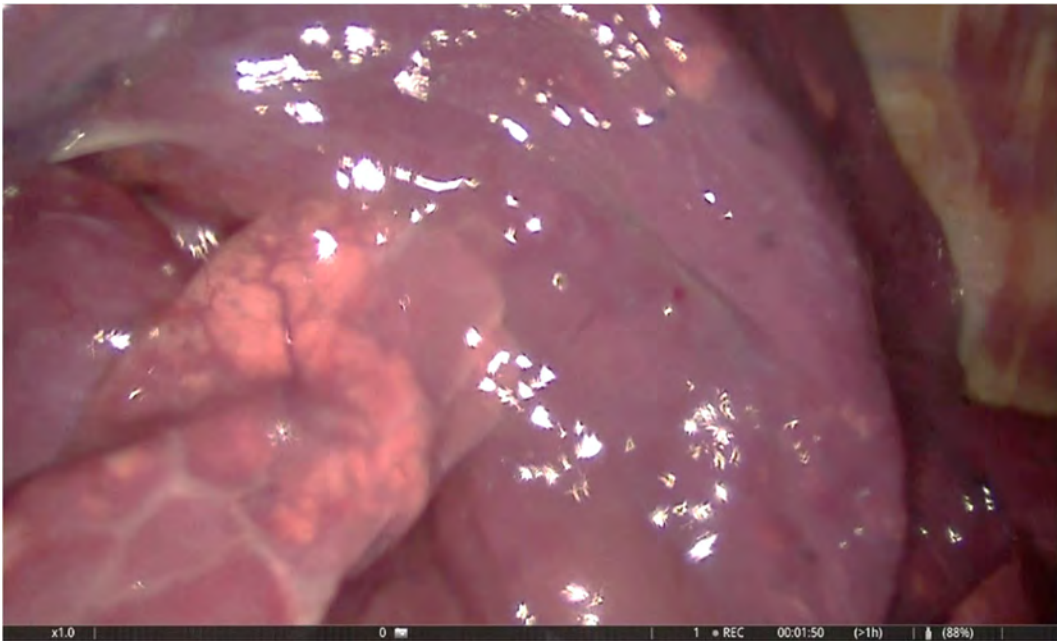
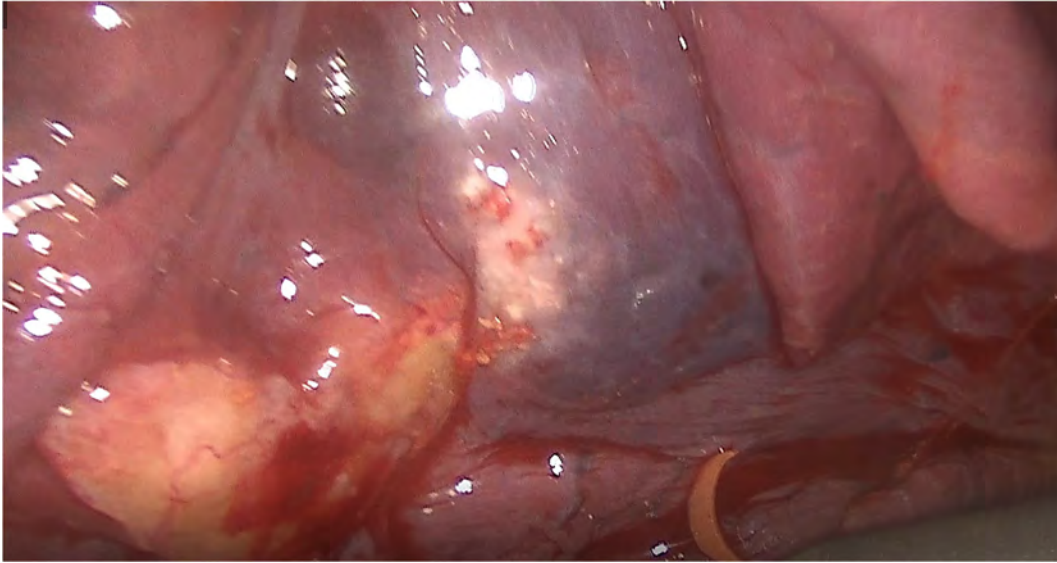
Fig. 1. Spiral computed tomography, Patient N., 55 years old

According to the CT results (06 October 2021): polytopic on both sides, more in the lower left part, there are foci with predominantly unclear scalloped contours from 4 to 14 mm (with the maximum size in the lower left part) with point inclusions of calcium in S7 on the right and S10 on the left. Numerous centrilobular and subpleural formations like bulls from 2 to 50x27 mm are seen (with the maximum size subpleurally paramedially in the lower left lobe). The lungs on the entire surface are evenly adjacent to the chest wall, have a normal vascular pattern. Lung roots are not changed. Trachea, main bronchi are normal, bronchi are traced up to subsegmental. Pulmonary pleural layers are thin, there is a small amount of fluid in the pleural cavity. The mediastinum is located on the midline, its size is within normal limits. Prevascular (in the thymus) 20x9 mm. Lymph nodes of the mediastinum are within normal limits.

In the conditions of the surgical department (21 November 2021) videothoracoscopy was performed, during which areas of powdered substance were found on the surface of the pleura (Fig. 2). Endoscopic resection of SVII of the lower lobe of the left lung with a cyst. A biopsy of the lung formations and mediastinal lymph nodes was performed. At the same time, drainage of the thoracic cavity was performed. Results of histologic examination (04 December 2021): in the studied material – a fragment of lung tissue with atelectasis, hemorrhage, inflammatory infiltration and cyst wall formed of fibrous tissue

without epithelial lining. In the specimen amorphous masses are presented in combination with the organized chronic giant cell granulomatous structure (a tophus), which contains clusters of crystals of MSU, intracellular eosinophilic deposits, numerous necrotic granules of various sizes located around epithelioid macrophages, lymphoplasmacytic cells and fibrovascular tissue (fibroplasia). The giant cell inflammatory response observed in the biopsy was more pronounced at the periphery. Single infiltrates in the form of eosinophilic deposits can be explained by the response of cells to the syndrome of prolonged compression with impaired microcirculation and the start of coagulant mechanisms. Cytological examination of pleural cavity fluid revealed the presence of crystals of MSU. The presence of crystals of MSU was confirmed by polarization microscopy.

According to the anamnesis of the disease, at the age of 38 the patient consulted a rheumatologist for moderate joint syndrome. During the collection of anamnesis it was established that a year ago for the first time there were complaints of pain, swelling and redness of the big toe, difficulty walking. She did not seek medical help, the inflammation stopped within 8 days. Such episodes began to appear almost every month, so the patient sought help from a family doctor, who referred her to a rheumatologist. The patient associates this condition with her work (constant physical activity) and nutrition.



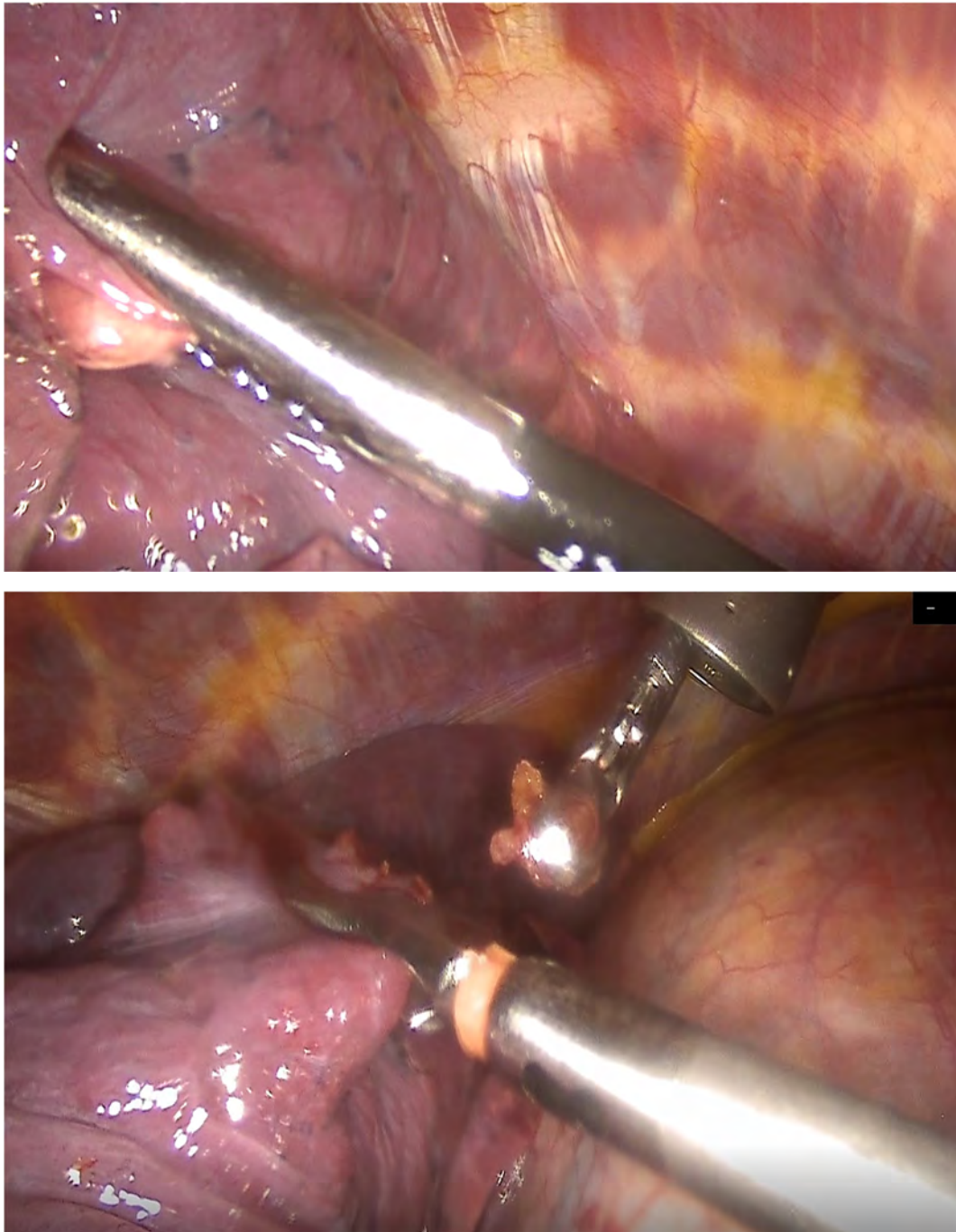


Fig. 2. Videothoracoscopy, patient N., 55 years old

At the time of examination by a rheumatologist deformity of the joints, moderate swelling of periarticular tissues, soreness of the 3d, 4th, 5th of metatarsophalangeal joints of the hands, knees, symptom of lateral compression, crepitation in the joints during movement were revealed. The total number of joints was 5, pain on VAS was 6 cm. There was moderate pain in the lumbar spine, in areas of paravertebral points. According to the radiographic study of the knee joints (2005), there were signs of deforming osteoarthritis, 1-2 stage with a slight decrease of the

joint space in the medial parts of the height, elongation of the closing plates of the vertebrae, a moderate decrease in the height between the vertebral discs in the middle thoracic region. The phenomenon of deforming spondylitis in the lower thoracic, lumbar spine. X-ray of the feet with the description is presented in Fig. 3. According to the ultrasound examination, the criterion of "double contour" of the ankle joints, arches of the foot, and metatarsophalangeal joint was established. The doctor diagnosed gout, chronic gouty arthritis. Allopurinol,

meloxicam were prescribed, the patient does not remember the doses. The patient took the drugs periodically without further consultation with the family doctor, as there was an improvement in general condition. The EULAR (2018) guidelines

outlined the diagnostic value of clinical algorithms and imaging techniques, such as the detection of UA crystals in synovial fluid, ultrasound examination and dual-energy CT.

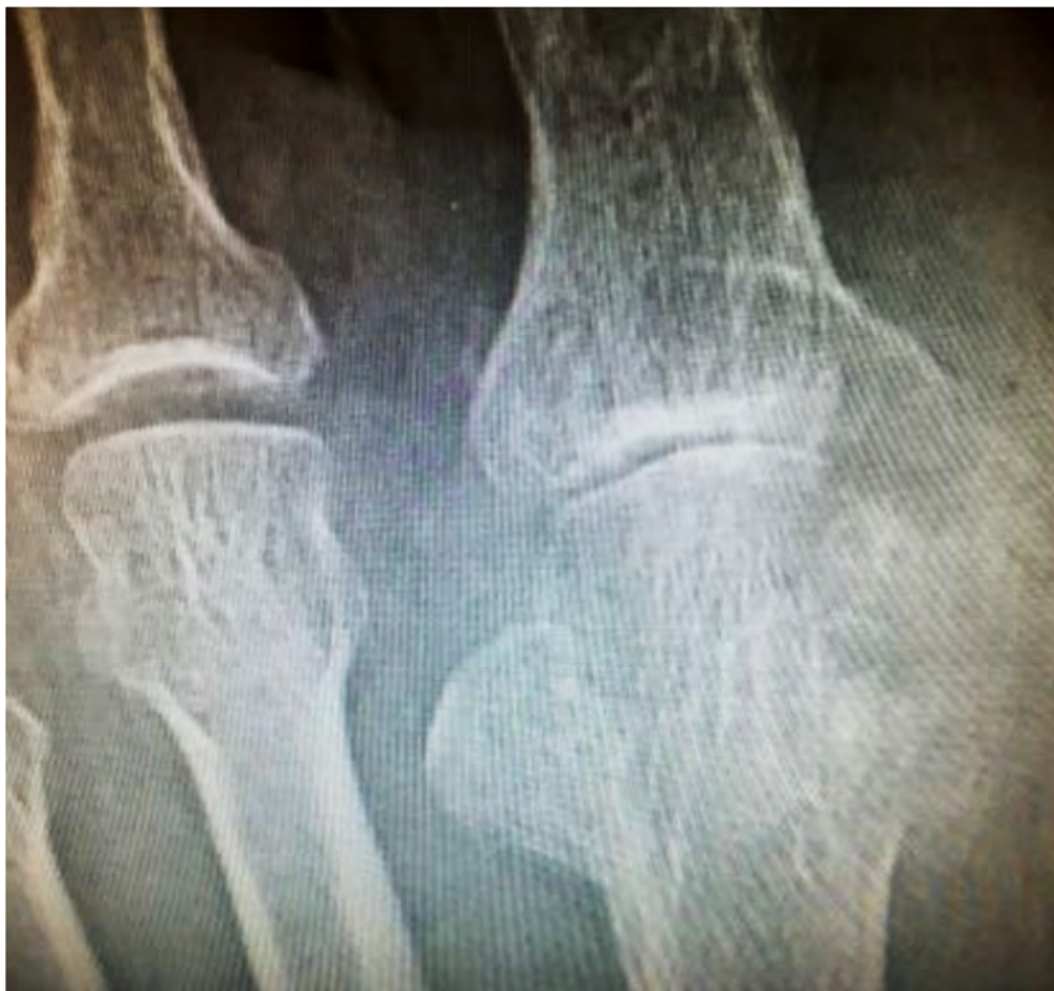

Fig. 3. X-ray of the feet, patient N., 55 years old (from the patient's archive). The presented image (X-ray of the feet in direct projection, the most informative fragment) determines the marginal erosion with tophus in the distal part of the metatarsal bone and the proximal phalanx of the big toe

At the age of 48, there was an asymmetry of the face on the right due to dense edema in the parotid gland, which lasted more than three months. Ultrasound examination of the anterior contour of the parotid gland on the right determined the formation of medium echogenicity, of irregular shape, up to 10.5 mm in diameter with clear uneven contours, of diffuse heterogenous structure. Epithelioid macrophages, single lymphoplasmocyte cells were found in the parotid gland punctate. Sjogren's disease was ruled out according to the ACR/EULAR criteria (no signs of focal lymphocytic sialoadenitis, no antibodies Anti-SSA/Ro, negative Schirmer test, saliva secretion without stimulation >0.1 ml/min). Recurrences were twice a year for up to a month. Treatment

for recurrent mumps, sialadenitis was performed in the department of maxillofacial surgery. The patient refused a biopsy of the parotid glands. Today, in saliva, even during remission, MSU crystals are found. In our opinion, the story of this patient has a continuation, which will depend on the effectiveness of prescribed urate-lowering therapy.

Except to Sjogren's disease, given the long course of hyperuricemia, eosinophilia in histological examination, differential diagnosis was made with a number of other diseases, including autoimmune diseases associated with IgG4 disease, sarcoidosis, histiocytosis.

During the exacerbation and the appearance of signs of pleural and pulmonary lesions, there was an

increase in the following indicators: erythrocyte sedimentation rate (from 19 to 45 mm/hr) and C-reactive protein (5.9-11 mg/L). The dynamics of UA levels (one result in different systems – mg/dL and $\mu\text{mol/L}$) on the background of treatment is presented in Table. When analyzing the changes in the level of MSU, it was found its decrease during an

exacerbation and lesions of lung and pleura manifestations. The latter can be explained by the intense deposition of MSU crystals in the tissues of the target organs. It is known that the mechanism of tophus formation is due to increasing hyperuricemia with subsequent deposition of MSU crystals in the tissues and an intensive decrease in UA levels.

The dynamics of UA levels on the background of treatment

Visit	Date of Collection	Treatment	Result of UA levels in different systems	
1	06-Dec-2021	Before receiving therapy	7.8 mg/dL	468 $\mu\text{mol/L}$
2	09-Dec-2021	From the beginning of therapy with Febuxostat: starting dose 40 mg/day	7.8 mg/dL	468 $\mu\text{mol/L}$
3	29-Dec-2021	Subsequent increase dose of Febuxostat: 80 mg/day	7.8 mg/dL	468 $\mu\text{mol/L}$
4	28-Jan-2022	Dose of Febuxostat: 80 mg/day	7.7 mg/dL	462 $\mu\text{mol/L}$
5	23-Feb-2022	Dose of Febuxostat: 80 mg/day	7.4 mg/dL	444 $\mu\text{mol/L}$
6	19-Mar-2022	Dose of Febuxostat: 80 mg/day	6.8 mg/dL	408 $\mu\text{mol/L}$
7	12-Apr-2022	Dose of Febuxostat: 80 mg/day	6.7 mg/dL	402 $\mu\text{mol/L}$
8	18-May-2022	Dose of Febuxostat: 80 mg/day	6.7 mg/dL	402 $\mu\text{mol/L}$
9	14-Jun-2022	Dose of Febuxostat: 80 mg/day	6.5 mg/dL	390 $\mu\text{mol/L}$
10	24-Jun-2022	Dose of Febuxostat: 80 mg/day	6.1 mg/dL	363 $\mu\text{mol/L}$

The presented case of untreated gout has led to significant structural disorders in such organs as lungs, pleura. Large tophus (like a tumor) with structural changes in the lung tissue caused chest pain. Endoscopic resection of the lower lobe of the left lung and revision of the thoracic cavity revealed atelectasis, hemorrhage, inflammatory infiltration, fibrous changes in tissues, amorphous masses with organized chronic giant cell granulomatous structure, is presented by MSU crystals, intracellular eosinophilic deposits, innate and adaptive immune cells and fibrovascular tissue.

A videothoracoscopy in this case was a means to present a visceral damage (lung, pleura) in gout and can give a better understanding of the natural course, pathophysiology and treatment of acute attacks. Unpredictable redistribution of monosodium salt urate crystals in the body can cause many disorders. The search for diagnostic tools to diagnose a severe

visceral complications with atypical localization in gout still remains unsolved.

Undoubtedly, the deposition of MSU crystals plays a central role in the development of gout; this is the main pathogenic mechanism of damage to target tissues and organs, which affects the clinical picture of the disease. It is known that in gout, lung damage leads to pneumonia and fibrosis through the primary response gene of myeloid differentiation (MyD88) and the signaling pathway of receptor 1 IL-1 (IL-1R1). Given the molecular mechanisms by which lung damage triggers IL-1beta production, inflammation and fibrosis, it is possible to determine the effectiveness of corrective treatment aimed at eliminating MSU crystals in tissues and prognosis [6, 10, 11].

Recent studies show that peripheral and cardiovascular deposition of UA crystals is much more common than previously known [12]. Systemic urate

deposition and chronic inflammation may be potentially associated with frequent comorbidities in gout. Khanna et al. In 2020 analyzed the literature on extraarticular deposition of UA crystals. Twenty-five articles reported on the deposition of UA crystals in the renal parenchyma (except nephrolithiasis) according to autopsy, histological and imaging methods. More than a hundred cases in the literature reported the deposition of UA crystals in the spine, with the first case detected in 1950. Deposition of MSU crystals was found in the cervical, thoracic and often lumbar spine according to autopsy, histopathological and surgical methods, imaging methods. The most common symptom was back pain, which often correlated with the location of MSU crystals. Some clinical reports estimate spinal symptoms as the initial manifestations of gout in 25% of patients. A retrospective analysis of patients with gout revealed deposits of MSU crystals in the spine in 60% of scans (83% of symptomatic and 25% of asymptomatic cases according to dual-energy computed tomography). Another prospective study of the lumbar sacral spine showed that patients with gout had significantly higher levels of MSU crystals in the spine than controls without gout, and the amount of deposits in the spine was proportional to blood UA levels.

Several articles reported the deposition of MSU crystals in the lungs, further formation of tophi and pulmonary nodules, which were detected by histological examination and imaging techniques [13].

The search for MSU crystals in synovial fluid or tophus aspirates is recommended for every patient with suspected gout, as the presence of MSU crystals allows to definitely diagnose gout [14].

This case demonstrates the difficulties in diagnosing and treating a severe visceral complications in atypical localization of gout.

CONCLUSION

1. Cases of gout with visceral complications have been reported to show specific macroscopic features of MSU crystals, including aortic valve, breast, lung lobe. In the patient we observe, crystals were found in pleural fluid, and sputum consisting of sodium urate, like the known facts of their appearance in the joint fluid and urine. UA salt crystals were also detected in the areas of pulmonary fibrosis formation according to the results of radiological examination, as well as endoscopic intervention in the lower lobe of the left lung.

2. Early detection of visceral complications in gout using modern diagnostic methods, timely adequate treatment with a multidisciplinary team of specialists can improve the prognosis and quality of life in this category of patients.

Contributors:

Kuzmina G.P. – conceptualization, methodology, investigation

Markova O.Ya. – methodology, resources

Lazarenko O.M. – conceptualization, validation

Funding. This research received no external funding.

Conflict of interests. The authors declare no conflict of interest.

REFERENCES

1. Aiguo M, Jingyan W, Zhang H, Dayong Wu. Analysis of Serum Ferritin and High Sensitive C Reactive Protein in Patients with Gout. *FASEB J.* 2017;31(1):lb414. doi: https://doi.org/10.1096/fasebj.31.1_supplement.lb414
2. Chen-Xu M, Yokose C, Rai SK, Pillinger MH, Choi HK. Contemporary Prevalence of Gout and Hyperuricemia in the United States and Decadal Trends: The National Health and Nutrition Examination Survey, 2007-2016. *Arthritis Rheumatol.* 2019;71(6):991-9. doi: <https://doi.org/10.1002/art.40807>
3. Fatima T, McKinney C, Major TJ, et al. The relationship between ferritin and urate levels and risk of gout. *Arthritis Res Ther.* 2018;20:179. doi: <https://doi.org/10.1186/s13075-018-1668-y>
4. Flais J, Bardou-Jacquet E, Deugnier Y, et al. Hyperferritinemia increases the risk of hyperuricemia in HFE-heredity hemochromatosis. *Joint Bone Spine.* 2017;84(3):293-7. doi: <https://doi.org/10.1016/j.jbspin.2016.05.020>
5. Kondratjuk VJe, Tarasenko OM. [A modern look at the pathogenetic aspects of gout (literature review)]. *Ukrainskyi revmatologichnyi zhurnal.* 2018;74(4):32-7. Ukrainian.
6. Dalbeth N, Gosling AL, Gaffo A, Abhishek A. Gout. *Lancet.* 2021;397(10287):1843-55. doi: [https://doi.org/10.1016/S0140-6736\(21\)00569-9](https://doi.org/10.1016/S0140-6736(21)00569-9)
7. Choi HK, McCormick N, Yokose C. Excess comorbidities in gout: the causal paradigm and pleiotropic approaches to care. *Nat Rev Rheumatol.* 2022 Feb;18(2):97-111. doi: <https://doi.org/10.1038/s41584-021-00725-9>
8. Oda K, Kikuchi E, Kuroda E, et al. Uric acid, ferritin and γ -glutamyltransferase can be informative in prediction of the oxidative stress. *J Clin Biochem Nutr.* 2019;64(2):124-8. doi: <https://doi.org/10.3164/jcbtn.18-23>
9. Ashiq K, Bajwa MA, Tanveer S, Qayyum M, Ashiq S, Khokhar R, Abid F. A comprehensive review on gout: The epidemiological trends, pathophysiology, clinical

presentation, diagnosis and treatment. *J Pak Med Assoc.* 2021;71(4):1234-8. doi: <https://doi.org/10.47391/JPMA.313>

10. Singh JA, Joseph A, Baker J, Richman JS, Shaneyfelt T, Saag KG, et al. SToRytelling to Improve Disease outcomes in Gout (STRIDE-GO): a multicenter, randomized controlled trial in African American veterans with gout. *BMC Med.* 2021;19(1):265. doi: <https://doi.org/10.1186/s12916-021-02135-w>

11. Singh JA, Gaffo A. Gout epidemiology and comorbidities. *Semin Arthritis Rheum.* 2020;50(3S):S11-S16. doi: <https://doi.org/10.1016/j.semarthrit.2020.04.008>

12. Klauser AS, Halpern EJ, Strobl S, Gruber J, Feuchtner G, Bellmann-Weiler R, et al. Dual-energy com-

puted tomography detection of cardiovascular monosodium urate deposits in patients with gout. *JAMA Cardiol.* 2019;4:1019-28. doi: <https://doi.org/10.1001/jamacardio.2019.3201>

13. Khanna P, Johnson RJ, Marder B, LaMoreaux B, Kumar A. Systemic Urate Deposition: An Unrecognized Complication of Gout? *J Clin Med.* 2020;9(10):3204. doi: <https://doi.org/10.3390/jcm9103204>

14. Richette P, Doherty M, Pascual E, et al. 2018 updated European League Against Rheumatism evidence-based recommendations for the diagnosis of gout. *Ann Rheum Dis.* 2020;79(1):31-8. doi: <https://doi.org/10.1136/annrheumdis-2019-215315>

Стаття надійшла до редакції
21.01.2022

