



UDC 616.688:616.14-007.64]-053.2-073

<https://doi.org/10.26641/2307-0404.2024.1.300597>

V.A. Digtiar¹, 
 D.G. Vernihora^{1, *}, 
 Yu.V. Zavorotnya³, 
 A.P. Gladkiy², 
 M.O. Kaminska¹ 

APPLICATION OF NEAR-INFRARED REFLECTANCE SPECTROSCOPY IN THE DIAGNOSIS OF VARICOCELE IN CHILDREN AND ADOLESCENTS

Dnipro State Medical University¹

Volodymyra Vernadskoho str., 9, Dnipro, 49044, Ukraine

*e-mail: kdethyrdma@gmail.com

Regional Family Health Medical Center²

Kosmichna str., 13, Dnipro, 49000, Ukraine

e-mail: info@odkl.org

Dnipro Regional Clinical Oncology Dispensary³

Havrylenka str., 1, Dnipro, 49000, Ukraine

e-mail: kz-kod-dor@ukr.net

Дніпровський державний медичний університет¹

вул. Володимира Вернадського, 9, Дніпро, 49044, Україна

КП «Регіональний медичний центр родинного здоров'я» ДОР»²

вул. Космічна, 13, Дніпро, 49000, Україна

КП «Дніпровський обласний клінічний онкологічний диспансер» ДОР»³

вул. Гавриленка, 1, Дніпро, 49000, Україна

Цитування: Медичні перспективи. 2024. Т. 29, № 1. С. 101-108

Cited: *Medicni perspektivi*. 2024;29(1):101-108

Key words: varicocele, Near-infrared reflectance spectroscopy, diagnosis, subinguinal microsurgical varicocelectomy, adolescents

Ключові слова: варикоцеле, Near-infrared reflectance spectroscopy, діагностика, субінгвінальна мікрохірургічна варикоцелектомія, підлітки

Abstract. Application of Near-infrared reflectance spectroscopy in the diagnosis of varicocele in children and adolescents. Digtiar V.A., Vernihora D.G., Zavorotnya Yu.V., Gladkiy A.P., Kaminska M.O. Varicocele is a venous anomaly characterized by the enlargement of the plexus of veins in the testicle. In pediatric cases, indications for surgical intervention in varicocele include palpable dilatation of the enlargement of the plexus veins, intermittent pain in the ipsilateral testicle, and a 20% reduction in size of the ipsilateral testicle compared to the contralateral healthy one. The limitations of evaluating these criteria and the need to assess semen parameters prompt clinicians to explore new diagnostic methods for timely surgical interventions in adolescents. One such promising study involves Near-infrared reflectance spectroscopy (NIRS) in the Near-infrared range. The aim of the research is to evaluate the diagnostic capabilities of NIRS in children with varicocele to determine the indications for surgical intervention. The study included 65 boys aged 11 to 17 years with left-sided grade III varicocele (main group) and 29 healthy boys as a control group. Monitoring of regional oxygen saturation (rSO_2) of testicular tissues was conducted using optical spectroscopy. NIRS examination of testicular tissues in both study and control groups showed statistically homogeneous data for regional oxygen saturation in the healthy (right) testicle. However, the NIRS study revealed significantly lower oxygen saturation (rSO_2) in the testicular tissue of the left testicle in patients with varicocele compared to the control group. The diagnostic significance of the difference in bilateral NIRS monitoring $\Delta rSO_2 > 13\%$ reliably characterized the presence of testicular hypotrophy by more than 20% compared to the healthy contralateral side (AUC=0.64, 95% CI (0.505-0.775), sensitivity – 79%, specificity – 50%, $p=0.042$). $\Delta rSO_2 > 11\%$ values indicated disturbances in spermogram related to oxidative stress (AUC=0.702, 95% DI (0.51-0.88), sensitivity – 82%, specificity – 61%, $p=0.031$). Therefore, NIRS study data have potential valuable information for the diagnosis and selection of treatment for varicocele in children. The research utilizing Near-infrared Reflectance Spectroscopy revealed a significant potential of this method for diagnosing and assessing the impact of varicocele on the microcirculation of testicular tissue in children. The diagnostic significance of the difference in bilateral monitoring using this non-invasive technique in determining the state of testicles and the possibility of addressing the question of the necessity of surgical intervention is established.

Реферат. Застосування спектроскопії в близькому інфрачервоному діапазоні в діагностиці варикоцеле в дітей та підлітків. Дігтяр В.А., Вернігора Д.Г., Заворотня Ю.В., Гладкий О.П., Камінська М.О. Варикоцеле – венозна аномалія, збільшення гроноподібного сплетення яєчка, яка викликає безпліддя та порушення функції яєчка. У дитячому віці показанням для оперативного втручання при варикоцеле є: пальповане

розширення вен грозноподібного сплетення, періодичний біль в інсипатеральному яєчку, зменшення інсипатерального яєчка на 20% порівняно з контралатеральним здоровим. Наявність цих критеріїв та обмежена можливість оцінити показники еякуляту змушують клініцистів шукати нові діагностичні методи, які допоможуть вчасно проводити оперативне втручання в підлітків. Одним з таких досліджень може стати Near-infrared reflectance spectroscopy (NIRS) – спектроскопія в близькому інфрачервоному діапазоні. NIRS дозволяє здійснювати безперервний моніторинг гемодинаміки й оксигенації шляхом вимірювання змін концентрації оксигенованого та дезоксигенованого гемоглобіну. Метою дослідження була оцінка діагностичних можливостей методики NIRS у дітей з варикоцеле для визначення показань до оперативного втручання. У дослідженні брали участь 65 хлопчиків віком від 11 до 17 років з лівобічним варикоцеле III ступеня (основна група) та 29 здорових хлопчиків в якості контрольної групи. Здійснювався моніторинг регіонарної насиченості тестикулярних тканин киснем (rSO_2) з використанням системи оптичної спектроскопії. Результати NIRS-дослідження тестикулярної тканини в дітей основної і контрольної груп показали статистично однорідні дані регіонарної насиченості киснем тканин здорового (правого) яєчка в обох групах, натомість NIRS-дослідження показали, що регіональна насиченість киснем (rSO_2) в тестикулярній тканині лівого яєчка була значно нижчою в пацієнтів з варикоцеле порівняно з контрольною групою. Установлено, що діагностичне значення різниці показників білатерального моніторингу $NIRS \Delta rSO_2 > 13\%$ достовірно характеризує наявність гіпотрофії яєчка більше ніж на 20% порівняно зі здоровим з контралатерального боку ($AUC=0,64$, 95 % ДІ (0,5-0,77), чутливість – 79%, специфічність – 50%, $p=0,042$), а значення $\Delta rSO_2 > 11\%$ свідчать про порушення в спермограмі, пов'язані з оксидативним стресом ($AUC=0,7$, 95% ДІ (0,51-0,88), чутливість – 82%, специфічність – 61%, $p=0,031$). Отже, дані NIRS дослідження мають потенційну корисну інформацію для діагностики та вибору лікування варикоцеле в дітей. Дослідження з використанням близької інфрачервоної спектроскопії виявило важливий потенціал цього методу для діагностики та оцінки впливу варикоцеле на мікроциркуляцію тестикулярної тканини в дітей. Установлена діагностична значущість різниці показників білатерального моніторингу з використанням цієї неінвазивної техніки у визначенні стану яєчок та можливості вирішення питання про необхідність хірургічного втручання.

Varicocele is a venous anomaly characterized by the enlargement of the plexus of veins within the scrotum. It holds the highest prevalence among urological disorders, affecting approximately 15% of males, both in adolescents and adult men.

Male infertility associated with varicocele is observed in 30-40% of cases of primary infertility and in 80% of patients with secondary infertility [1]. Virtually all patients with varicocele experience damage to the testicular parenchyma, leading to a reduction in testicular volume, spermatogenesis dysfunction, changes in hormonal production, and damage to sperm DNA. The mechanism of testicular dysfunction in idiopathic varicocele is secondary and arises from an increase in temperature within the scrotal cavity and oxidative stress. Indirect evidence of the dependence of spermatogenesis and testicular function on temperature is seen in similar changes in cryptorchidism [2].

Other studies indicate that changes in varicocele are dependent on transient hypoxia and the presence of oxidative stress in the testicle due to venous congestion [3].

Standard diagnostic methods for varicocele in children differ significantly from those in adults. In adulthood, diagnostic criteria for varicocele include palpable enlargement of the plexus of veins, infertility in a marriage with a woman of normal fertility, and changes in the semen analysis. These criteria are reliable and practically do not raise additional questions regarding the indications for surgical intervention [4].

In childhood, due to the inability to apply the criteria mentioned above, indications for surgical intervention are as follows: palpable enlargement of the plexus of veins, intermittent pain in the ipsilateral testicle, and a 20% reduction in the size of the ipsilateral testicle compared to the contralateral healthy one [5]. The presence of only these criteria and the inability to assess semen parameters compel clinicians to search for new diagnostic criteria that will help identify new predictors, prompting timely surgical intervention in adolescents.

One of such study could involve Near-infrared Spectroscopy (NIRS), which operates in the Near-infrared range. NIRS allows continuous monitoring of hemodynamics and oxygenation by measuring changes in the concentration of oxygenated and deoxygenated hemoglobin. With a sufficient number of observations, this method may become one of the predictors for considering surgical intervention in childhood in the future, especially when standardized investigations are not feasible, and it can complement existing diagnostic approaches.

The aim of the study: assessment of the diagnostic capabilities of the NIRS methodology in children with varicocele for determining indications for surgical intervention.

MATERIALS AND METHODS OF RESEARCH

The research was conducted at the Department of Urology and Reconstructive Surgery of the Municipal Enterprise "Regional Medical Center for Family Health" in Dnipro city. The study was carried out

within the framework of a PhD dissertation. The research has been approved by the Biomedical Ethics Committee of DSMU (protocol 8, dated 2020) and conducted in accordance with the written consent of participants, parents, or guardians of children, as well as in accordance with the principles of bioethics outlined in the Helsinki Declaration "Ethical Principles for Medical Research Involving Human Subjects" and the "Universal Declaration on Bioethics and Human Rights (UNESCO).

Inclusion criteria for the study were as follows: boys under the age of 18, a verified diagnosis of grade III varicocele in combination with intermittent pain in the ipsilateral testicle or testicular hypotrophy of more than 20% compared to the healthy contralateral side, and the presence of signed informed consent from parents for the surgical intervention.

The diagnosis of varicocele was established according to the standard classification by Dubin, where the first degree involves the expansion of the plexus of veins detectable only by palpation during the Valsalva maneuver in a vertical position. The second degree involves palpable enlargement of the plexus of veins at rest. The third degree involves visible expansion of the plexus of veins through the skin [6].

Exclusion criteria from the study were as follows: the presence of aorto-mesenteric compression, varicocele caused by abdominal masses or tumors, May-Thurner syndrome, and isolated grade III varicocele.

Aorto-mesenteric compression was excluded based on the absence of the standard triad of symptoms: varicocele, malignant hypertension, and hematuria [7].

Abdominal masses and tumors were ruled out during screening ultrasound examinations. May-Thurner syndrome and isolated right varicocele were excluded based on the absence of pathological processes in the contralateral right testicle [6].

Out of the 70 examined patients, 65 children met the inclusion criteria for the study. Their ages ranged from 11 to 17 years (mean age – 16 (15; 17) years), and they had left-sided grade III varicocele (main group). For comparison of NIRS indicators in healthy children, a control group was formed with 29 boys aged 10 to 17 years, with a mean age of 16 (14; 16) years (no significant difference between groups, $p=0.108$ according to the U-criterion).

For the diagnosis of hypoxic-ischemic changes in the testicular parenchyma and the diagnosis of enlargement of the plexus of veins, physical examination, ultrasound with Doppler mapping in both vertical and horizontal positions in combination with the Valsalva maneuver were applied.

Standard clinical and instrumental examinations were complemented by a semen analysis in children older than 16 years who had prior manual experience

and, together with their parents, provided informed consent. Additionally, regional oxygen saturation measurements (rSO_2) were taken, providing information about the local balance between oxygen delivery and demand. NIRS investigations were conducted on both the healthy right testicle and the left testicle with varicocele. The optical spectroscopy system used for the study was the INVOS Somatic Oximetry Medtronic, applied continuously for 2 hours with two sensors on the volar and dorsal surfaces of the scrotum over each testicle. The testicles were manually mobilized close to the skin and secured. Data were recorded every 15 seconds, displaying absolute values on the monitor as a percentage, with a real-time tissue oxygenation monitoring graph on the INVOS monitor, and information recorded on an electronic storage device for subsequent statistical processing. Monitoring was performed for 2 hours on each side, totaling 480 measurements with the determination of the average indicator for each testicle. To eliminate false results or the inclusion of artifacts in statistical processing, zero values of rSO_2 and changes exceeding 30 within 4 consecutive measurements were excluded. In addition to the measured rSO_2 values on the right and left sides, the difference index between them was calculated: $\Delta rSO_2 = rSO_2 \text{ right} - rSO_2 \text{ left}$.

The tissue oxygenation monitoring pattern is standardized [8], but the methodology and data interpretation during testicular spectroscopy were adjusted not for acute circulatory disorders but for chronic tissue ischemization.

Statistical analysis of the research results was performed using STATISTICA v. 6.1 (StatSoft Inc., USA, serial number AGAR909E415822FA) and MedCalc Software trial version 20.218 (MedCalc Statistical Software Ltd, Ostend, Belgium; <https://www.medcalc.org>; 2023) – an open-access internet resource [9].

Considering the deviation of the distribution of most quantitative variables from the normal law by the Shapiro-Wilk criterion, non-parametric characteristics and methods of analysis were used: median (Me) with interquartile range (25%; 75% percentile), Mann-Whitney U test for independent samples. For qualitative variables, the Pearson chi-square test (χ^2), including Yates' continuity correction, was used. The relationship between features was assessed using Spearman's rank correlation coefficients (rs). The diagnostic criteria of NIRS investigation as predictors for determining indications for surgical intervention were evaluated using ROC analysis with the calculation of the area under the ROC curve (AUC) with a 95% confidence interval (CI), determination of the optimal cutoff point, and the corresponding

sensitivity and specificity indices. Values of $p < 0.05$ were considered statistically significant.

RESULTS AND DISCUSSION

The general and clinical characteristics of patients in the main group at the beginning of the study are presented in Table 1. From the table, it can be observed that nearly 75% of patients with grade III varicocele complained of pain in the ipsilateral tes-

ticle, while 44% exhibited a reduction in the size of the left testicle by 20% or more compared to the contralateral testicle. Additionally, among 41 adolescents aged over 16 years, 28 (68%) showed evidence of spermatogenic impairment. Ultrasound examination with Doppler mapping revealed sonographic signs of altered perfusion in the testicular tissue, characterized by significant increases in blood flow velocity and the dimensions of the spermatic vein.

Table 1

General and clinical characteristics of patients in the main group at the beginning of the study

Indicator	All patients (n=65)
Age, years	16 (15; 17)
BMI, kg/m ²	19,1 (18,3; 21,1)
<i>Sexual maturity stage (Tanner scale):</i>	
- 4	25 (38%)
- 5	40 (61%)
Presence of pain	48 (73%)
Contralateral (right) testicle volume, cm ³	10,6 (7,8; 13,1)
Ipsilateral (left) testicle volume, cm ³	7,9 (5,6; 10,5)
Testicular atrophy	29 (44%)
Diameter of spermatic vein without Valsalva maneuver, mm	3,7 (3,1; 4,0)
Diameter of spermatic vein with Valsalva maneuver, mm	5,0 (4,0; 5,5)
Blood flow velocity, sec	5,0 (4,0; 6,8)
<i>Spermogram parameters:</i>	
	(n=41)
- Normozoospermia	13 (31%)
- Oligozoospermia	21 (51%)
- Asthenozoospermia	7 (17%)

Note. Data are presented as Me (25%; 75%) or abs. (%).

NIRS examination of testicular tissue in children from the main and control groups revealed statistically consistent data on regional tissue oxygen saturation of the healthy (right) testicle in both groups: 60% (51; 63) in the main group and 57% (54; 61) in the control group ($p > 0.05$). However, significant differences ($p < 0.001$) between the observation groups were found regarding the rSO_2 values of the left testicle with varicocele, which were 1.3 times lower than in the control group: 41% (34; 47) versus 55% (53; 62). Overall, the difference in rSO_2 measurements between the right and left testicles (ΔrSO_2) in healthy children ranged from - 3% to 4% with a

median of 1% (-1; 2), while in children with grade III varicocele, the disparities were more substantial, varying from 3% to 37% with a median of 16% (11; 22) at $p < 0.001$ between the groups (Table 2).

According to the results of ROC analysis, the difference of more than 4% ($\Delta rSO_2 > 4\%$) between bilateral measurements of NIRS testicular tissue parameters in children can serve as a clear diagnostic criterion for impaired blood flow in the testicle with varicocele: the area under the ROC curve (AUC) is 0.999, 95% CI (0.99 – 1.0), with sensitivity of 96% and specificity of 100% at $p < 0.001$.

Table 2

Average rSO₂ values in children from the main and control groups based on NIRS monitoring

Indicator	Research Group		Differences between Groups (p)*
	main group (n=65)	control group (n=29)	
rSO ₂ of the right testicle, %	60 (51; 63) °	57 (54; 61)	0,847
rSO ₂ of the left testicle, %	41 (34; 47) °	55 (53; 62)	<0,001
Δ rSO ₂ , %	16 (11; 22)	1 (-1; 2)	<0,001

Notes: data are presented as Me (LQ; HQ); * – based on Mann-Whitney U test; ° – p<0.001 for comparisons (by Mann-Whitney U test).

Correlation analysis of NIRS measurements and other characteristics in patients from the main group revealed significant associations of bilateral differences in rSO₂ measurements with ipsilateral testicular hypotrophy (rs=0.241; p=0.050), including

the percentage reduction in its size compared to the contralateral testicle (rs= -0.256; p=0.040), as well as with abnormalities in spermogram results (rs=0.326; p=0.037), which are essential diagnostic criteria for varicocele requiring surgical intervention (Table 3).

Table 3

Average Δ rSO₂ measurements in children from the main group depending on the presence or absence of trophic disorders in the ipsilateral testicle and abnormalities in the spermogram (based on NIRS monitoring)

Parameter	Presence of the characteristic	Absence of the characteristic	Differences between measurements (p)*
Testicular atrophy	18 (14; 23)	14 (10; 21)	0,050
Abnormal spermogram	19 (13; 23)	10 (7; 17)	0,039

Notes: data are presented as Me (LQ; HQ); * – using the Mann-Whitney U-test.

Furthermore, a tendency towards increased blood flow velocity in the testicular tissue and enlargement of the testicular vein (without Valsalva maneuver) was observed with an increase in the Δ rSO₂ measurements: rs=0.204, p=0.102, and rs=0.206, p=0.10, respectively. By the way, unilateral rSO₂ measurements did not show significant correlations with the investigated characteristics, except for mutual dependence (rs=0.459, p<0.001). This indicates the low informativeness of separate rSO₂ measurements on the testicles as predictors for determining the indications for surgical intervention in children with varicocele.

At the same time, the diagnostic significance of the difference in bilateral NIRS monitoring (Δ rSO₂) as predictors for choosing the treatment strategy for varicocele is confirmed by the results of the conducted ROC analysis. It has been established that Δ rSO₂ values >13% reliably characterize the presence of testicular hypotrophy of more than 20% compared to the healthy contralateral side (AUC=0.64, 95% CI (0.5-0.77), sensitivity – 79%,

specificity – 50%, p=0.042), and Δ rSO₂ values >11% indicate spermogram abnormalities associated with oxidative stress (AUC=0.702, 95% CI (0.51-0.88), sensitivity – 82%, specificity – 61%, p=0.031) (Fig.).

NIRS – Near-infrared Spectroscopy, allows continuous monitoring of hemodynamics and oxygenation by measuring changes in the concentration of oxygenated and deoxygenated hemoglobin.

Human tissues are characterized by the property of transmitting light in the Near-infrared (NIR) spectrum range. During the passage of a light beam through biological tissues, pigmented compounds known as chromophores, absorb light (600-1000 nm). The light-absorbing property of chromophores is most sensitive in the body to oxyhemoglobin and deoxyhemoglobin.

Morphometric studies of the vascular system have shown that approximately 75-85% of the volume is attributed to the venous component. As NIRS is not dependent on the pulsatile wave, the data indicate an average (practically 85% venous) concentration of oxyhemoglobin, providing information about the

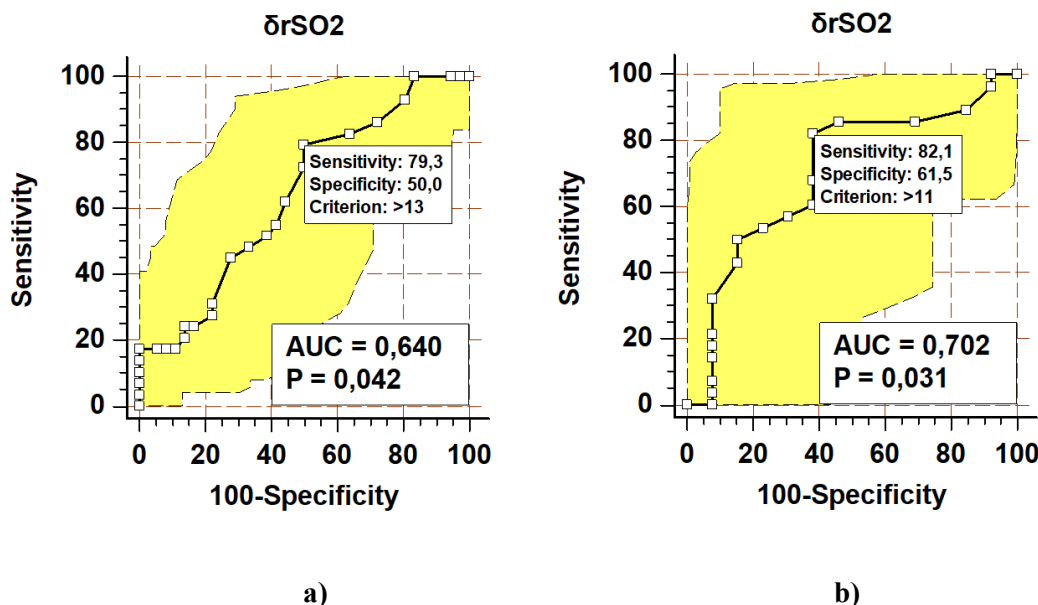
local balance between oxygen delivery and demand. The venous component dominates in varicose dilatation of the enlargement of the plexus veins.

Furthermore, testicular biopsies from men with varicocele have provided histological evidence that varicose dilatation of the enlargement of the plexus veins leads to blood stasis in microcirculatory vessels, resulting in ischemic structural changes at the cellular level. Evidence of hypoxia in men with varicocele has also been investigated at the molecular level. In a study [11], higher expression of hypoxia-inducible factor 1 α , a key regulator in tissue response to hypoxia, was noted. Another confirmation of the theory that varicocele reduces local blood flow to the testicle comes from studies demonstrating improved arterial hemodynamics in the testicle after varicocelectomy.

Classically, NIRS was used primarily for measuring cerebral oximetry, abdominal splanchnic oximetry, and cerebral oxygenation in neonatology, particularly in cases of congenital heart defects.

As it is known, the penetration depth of light in biological tissues depends on both its wavelength and the absorbing properties of the tissues. Near-infrared light is primarily absorbed by the skin, but a portion of it (about 30%) can penetrate up to 30 mm deep, reaching the subcutaneous fat layer and the organs beneath it. On the one hand, this penetrating property of Near-infrared light and the relatively thin covering tissues make NIRS impractical for children of other age groups. On the other hand, it allows for the assessment of oxygenation in organs like the testicles due to the absence of subcutaneous fat and the mobility of the testicles (with their proximity to the skin).

Considering the research results, this method may become one of the predictors for considering surgical intervention in pediatric cases in the future, especially when standardized examinations are not feasible. Interpreting the obtained data and extrapolating them to practical medicine, a new indication for surgical intervention in pediatric varicocele could be defined as $\Delta rSO_2 > 13\%$ between the left and right testicles.



ROC curves of the difference in bilateral NIRS monitoring (ΔrSO_2) in the presence of ipsilateral testicular atrophy (a) and spermogram abnormalities (b)

Near-infrared Spectroscopy allows continuous monitoring of hemodynamics and oxygenation by measuring changes in the concentration of oxygenated and deoxygenated hemoglobin [10]. Human tissues have the property of transmitting light in the Near-infrared (NIR) spectrum range. During the passage of a light beam through biological tissues, pigment compounds known as chromophores absorb light (600-1000 nm).

Traditionally, NIRS was used in the prism of measurement of cerebral oximetry, abdominal splan-

chnic oximetry, and cerebral oxygenation in congenital heart defects in neonatology [12]. The penetration depth of the NIRS light into biological tissues depends on both the length and the absorbing properties of the tissues. Near-infrared radiation is mainly absorbed in the dermis, but some of it (about 30%) penetrates to a depth of up to 30 mm, reaching the subcutaneous fat layer and the organs located beneath it. On the one hand, this penetrating property of NIR radiation and the thinness of the covering tissues in newborns make NIRS impractical for

children of other age groups. On the other hand, it allows the assessment of oxygenation in organs such as the testicle, due to the absence of fat tissue under the skin and the mobile nature of the testicle (close proximity to the skin) [13].

Taking into consideration the results of the study, it can be considered that this method may potentially become one of the predictors for initiating consideration of surgical intervention in childhood when standardized examinations are not yet feasible and will complement existing ones. Interpreting the obtained data and extrapolating them to practical medicine, a new indication for initiating surgical intervention in pediatric varicocele can be highlighted – the significance of $\Delta rSO_2 > 13\%$ between the left and right testicles. Furthermore, $\Delta rSO_2 > 13\%$ values reliably characterize the presence of testicular hypotrophy by more than 20% compared to the healthy contralateral side (AUC=0.64, 95% CI (0.5-0.77), sensitivity – 79%, specificity – 50%, $p=0.042$), and $\Delta rSO_2 > 11\%$ values indicate disturbances in spermogram related to oxidative stress (AUC=0.702, 95% CI (0.51-0.88), sensitivity – 82%, specificity – 61%, $p=0.031$).

CONCLUSION

1. Research using Near-infrared spectroscopy has revealed the significant potential of this method for

diagnosing and assessing the impact of varicocele on the microcirculation of testicular tissue in children.

2. It has been determined that the diagnostic value of the difference in bilateral monitoring of Near-infrared reflectance spectroscopy $\Delta rSO_2 > 13\%$ reliably characterizes the presence of testicular hypotrophy by more than 20% compared to the healthy side (AUC=0.64, 95% CI (0.5-0.77), sensitivity – 79%, specificity – 50.0%, $p=0.042$).

3. It has been established that the diagnostic value of $\Delta rSO_2 > 11\%$ indicates disturbances in the spermogram associated with oxidative stress (AUC=0.702, 95% CI (0.51-0.88), sensitivity – 82%, specificity – 61%, $p=0.031$).

Contributors:

Digtyar V.A. – conceptualization, methodology, writing of the original text;

Vernihora D.G. – conceptualization, methodology, writing of the original text, resources, investigation, data curation;

Zavorotnya Yu.V. – resources, editing;

Gladkiy O. P. – resources, data curation;

Kaminska M.O. – investigation, data curation.

Funding. This research received no external funding.

Conflict of interests. The authors declare no conflict of interest.

REFERENCES

- Zundel S, Szavay P, Stanasel I. Management of adolescent varicocele. *Semin Pediatr Surg.* 2021 Aug;30(4):151084. doi: <https://doi.org/10.1016/j.sempedsurg.2021.151084>
- Bertolotto M, Freeman S, Richenberg J, Belfield J, Dogra V, Huang DY, et al. Members of the ESUR-SPIWG WG. Ultrasound evaluation of varicoceles: systematic literature review and rationale of the ESUR-SPIWG Guidelines and Recommendations. *J Ultrasound.* 2020 Dec;23(4):487-507. doi: <https://doi.org/10.1007/s40477-020-00509-z>
- Dieamant F, Petersen CG, Mauri AL, Conmar V, Mattila M, Vagnini LD, et al. Semen parameters in men with varicocele: DNA fragmentation, chromatin packaging, mitochondrial membrane potential, and apoptosis. *JBRA Assist Reprod.* 2017 Dec 1;21(4):295-301. doi: <https://doi.org/10.5935/1518-0557.20170053>
- Su JS, Farber NJ, Vij SC. Pathophysiology and treatment options of varicocele: An overview. *Andrologia.* 2021 Feb;53(1):e13576. doi: <https://doi.org/10.1111/and.13576>
- Silay MS, Hoen L, Quadackaers J, Undre S, Boogaert G, Dogan HS, et al. Treatment of Varicocele in Children and Adolescents: A Systematic Review and Meta-analysis from the European Association of Urology/European Society for Paediatric Urology Guidelines Panel. *Eur Urol.* 2019 Mar;75(3):448-61. doi: <https://doi.org/10.1016/j.eururo.2018.09.042>
- Macey MR, Owen RC, Ross SS, Coward RM. Best practice in the diagnosis and treatment of varicocele in children and adolescents. *Therapeutic Advances in Urology.* 2018;10(9):273-82. doi: <https://doi.org/10.1177/1756287218783900>
- Kaba A, Kaba E, Ardic C. A Rare Cause of Unexplained Left Flank Pain: Nutcracker Syndrome. *Konuralp Medical Journal.* 2023;15(2):273-6. doi: <https://doi.org/10.18521/ktd.1106258>
- Laher AE, Swart M, Honiball J, et al. Near-infrared spectroscopy in the diagnosis of testicular torsion: valuable modality or waste of valuable time? A systematic review. *ANZ journal of surgery.* 2019;90(5):708. doi: <https://doi.org/10.1111/ans.15402>
- Antomonov MJ, Korobeinikov GV, Hmelnytska IV, Harkovliuk-Balakina NV. [Mathematical methods of processing and modeling the results of experimental research: a study guide]. Kyiv: Olimpiiska literatura; 2021. 216 p. Ukrainian.
- Stothers L, Shadgan B, Macnab A. Urological applications of near infrared spectroscopy. *Can J Urol.* 2008 Dec;15(6):4399-409. PMID: 19046493.
- Vivas-Acevedo G, Lozano JR, Camejo MI. Effect of varicocele grade and age on seminal

parameters. *Urologia internationalis*. 2010;85(2):194-9.
doi: <https://doi.org/10.1159/000314226>

12. Vlasov A. Features of cerebral oximetry indicators in different types of combined anesthesia in children with congenital surgical pathology. *Emergency medicine*. 2021;17(1):44-9.
doi: <https://doi.org/10.22141/2224-0586.17.1.2021.225720>

13. Chen K-Y, Wanniarachchi H, Lang Y, et al. Neural correlates of newsvendor-based decision making in the human brain: An exploratory study to link neuroeconomics with neuroimaging using fNIRS [Internet]. 2020 [cited 2023 Jul 19]. 21 p.
doi: <https://doi.org/10.1101/2020.02.08.940197>

Стаття надійшла до редакції 14.09.2023;
затверджена до публікації 24.01.2024

