

O. AVRUNIN, A. TRUBITCIN, O. ISAEVA, V. KLYMENKO

## POSSIBILITIES FOR ASSESSING THE EFFECTIVENESS OF TREATMENT OF ATOPIC DERMATITIS BASED ON ANALYSIS OF COLOR CHARACTERISTICS OF VIDEO DERMATOSCOPIC IMAGES

The **subject** of the article is the study of the color characteristics of video dermatoscopic images of affected skin areas of children with atopic dermatitis and the development of an automated diagnostic system for processing and analysis of dermatoscopic images. The **aim** of the work is to develop an objective method for assessing the skin condition of children with atopic dermatitis based on numerical analysis of images of affected skin areas. The **objectives** of the work were to collect a life history of children with atopic dermatitis, study the color characteristics of video dermatoscopic images of affected skin areas and further develop an automated diagnostic system for processing and analyzing dermatoscopic information. **Research Methods.** During the diagnostic examinations of children with atopic dermatitis, a history of life was collected and the initial dermatological status of patients was described. A comprehensive assessment of the severity of the disease was performed using the SCORAD index. Image registration was carried out using a UM039 digital video dermatoscope with optical magnification up to 200 times, resolution of the receiving matrix  $2880 \times 1800$  image elements, equipped with a built-in block of adjustable LED lighting, a tripod and a rotary 3-inch display. The images were captured on a microSD card with subsequent transfer of data to the database on the computer. The **results** of the study, based on the data obtained, allowed us to assess the intensity and dynamics of the inflammatory processes of the affected areas of the skin of children with atopic dermatitis and to formulate the principles of the automated diagnostic system for processing and analysis of dermatoscopic images. **Conclusion.** At the end of the study, the authors conclude that to monitor the skin condition in the treatment of atopic dermatitis, the analysis of the color components of the affected areas on the HSV scale can be used, which allows the specialist to intuitively observe the results of the therapy in a natural color space for human perception. As prospects for the development of the work, the authors substantiate the prerequisites for the development of a complete automated system for the comprehensive diagnosis of atopic dermatitis and its clinical trial. Such a system can make it possible to form a preliminary diagnosis and determine the severity of the disease based on the evaluation of color channels of images of affected skin areas and additional diagnostic data.

**Keywords:** atopy; dermatitis; brightness; HSV; color.

### Formulation of the problem

Atopic dermatitis (ATD) is one of the most common skin diseases that affects up to 20% of children and 2-8% of the adult population [1].

The disease has a significant impact on the quality of life of the patient and his family, causing sleep disturbance, decreased productivity, emotional and mental problems, impaired physical activity and social life [2]. It can be a cause of disability.

Atopic dermatitis (ATD), a multifactorial inflammatory-immunopathological disease, is characterized by a relapsing course, accompanied by intense itching, more often in infancy and early childhood. Atopic dermatitis is currently one of the most common chronic diseases. For many years, it was believed that the first manifestations of atopy, such as a hereditary predisposition to IgE-associated environmental allergens and atopic march, ultimately lead to the development of asthma and allergic rhinitis. In support of this, all studies of past years were focused on the study of the humoral and T-cell immune response, and the results cast doubt on the main role of allergic mechanisms in the development of atopy, although they did not reduce the importance of immune responses. Modern molecular studies increasingly indicate the important role of the epidermis and its barrier function as the main link in the development of atopic processes.

One of the most important risk factors today is considered a hereditary predisposition to atopic diseases, in particular to AD. Various studies show that with an existing atopic disease in family members, the probability of manifestation of an atopic condition in the next

generation exceeds 80%. The hereditary predisposition to AD is realized under the influence of environmental factors and the lifestyle of the individual. Among them are the so-called Western diet with a high content of sugar and polyunsaturated fatty acids; Other factors include living in urban areas and regions with weak exposure to ultraviolet radiation and low humidity, as well as the small composition of the family with a high level of education of its members.

One of the fundamental genetic risk factors for the development of atopic dermatitis is considered to be a zero mutation in the filaggrin gene. This protein is formed from profilaggrin through proteolysis in keratogialin granules and plays a role in the aggregation of keratin filaments in the upper layers of the epidermis, holding lipids and proteins together between keratinocytes of the stratum corneum. In addition, filaggrin affects the differentiation of cells and promotes the formation of components of a natural moisturizing factor, which are of great importance for skin hydration. Recently, it has also been found that by inhibiting the generation of house dust mite antigen, filaggrin can directly affect allergens. There is evidence that the absence of filaggrin breakdown products contributes to transepidermal water loss, allergen penetration and skin colonization of *Staphylococcus aureus*. This explains why a higher level of total IgE, more pronounced sensitization, a more severe course of AD, and the development of asthma are associated with a filaggrin mutation and loss of its function.

For a long time, these features were considered as secondary effects of immunological mechanisms. Nevertheless, the insight of genetically determined epidermal defects, which contribute to the development of

atopic dermatitis, has shifted the focus of the problem toward breaking the epidermal barrier. It is important to note that the violated epidermal barrier is not limited to defects in the structural proteins of the skin and is found not only in carriers of the filaggrin protein gene mutation. Other hereditary factors, environmental factors, such as the use of soap, detergents, exposure to exogenous proteases (for example, house dust mites), as well as repeated damage to the integrity of the epidermis (excoriation) worsen the condition of the skin. Thus, various combinations of hereditary and exogenous factors are involved in violations of the epidermal barrier. Important data presented by T. Werfel et al. Indicate that dysfunction of the barrier properties of the skin of newborns is also a prognostic factor in food allergy, which confirms the theory of percutaneous sensitization to allergens. The detected changes that affect the deterioration of the skin, mainly in open areas exposed to aeroallergens, increase sensitization in patients with AD and suggest that due to epidermal barrier dysfunction, prolonged exposure of the agent is accompanied by direct penetration of allergens into the skin.

A distinctive feature in the development of AD is inflammation in the skin, which is characterized by consistent and progressive models of inflammatory cell infiltration, in particular CD4 + cells. Signs of subclinical inflammation with an increase in the number of T helper cells (Th2 and Th22 and to a lesser extent Th17) and a pro-inflammatory cytokine environment are already detected on the visually unaffected skin of children with AD. Enhanced T cell infiltration expresses various skin adhesion molecules, such as cutaneous lymphocytic antigen, chemokines, and lipid chemotactic receptors that penetrate various layers of the skin. In addition, an increase in the number of Th2-cytokine-producing lymphocytes in the affected areas with atopic dermatitis leads to increased inflammation in the skin. In a systematic review of 113 studies, no clear evidence was found of the relationship between the role of specific infections or vaccination in the manifestation of AD, but the dependence of the development of AD on the use of broad-spectrum antibiotics during pregnancy and the postpartum period was found [3].

Sometimes a person can suffer from AD throughout life – from infancy to death. During the year, periods of exacerbation and hyperemia are also periodically observed, manifested by a change in the color of the skin.

In children with the initial stage of AD, subject to the timely appointment of a hypoallergenic diet and elimination measures, external therapy and drug treatment, in many cases it is relatively easy to achieve the reverse development of skin rashes, whereas with untimely and inadequate therapy, the transition from the initial stage of AD to the stage of pronounced changes is noted on the skin.

At the stage of marked changes in patients, along with eczematous changes and peeling of the skin, the appearance of lichenization was noted. Around the foci, the appearance of papular elements or plaques was noted. Patients were worried about severe itching of the skin. In unaffected areas of the skin, 73% of the observed

patients showed red, and in 27%, white dermographism [4].

In conditions of a prolonged chronic course of the disease, the problem of an objective assessment of the severity of skin lesions at each particular moment of the disease becomes particularly relevant. Both the volume of therapy for stopping a particular exacerbation and the development of a patient management strategy will depend on this assessment [5, 6].

Currently, one of the most informative methods for assessing the condition of the skin during dermatological studies is considered to be dermatoscopy. The modern market of dermatoscopes is represented by a wide selection of samples, distinguished by their functionality and price range.

The VEOS DS3 dermatoscope (fig. 1) is a portable digital dermatoscope with a touch screen, an improved lighting system, which allows the study of skin, subcutaneous structures and vascular pattern. Dermatoscopy can be performed by contact and non-contact methods (non-polarizing and polarizing methods). Focus adjustment can be carried out both in manual and automatic modes. The design features of the optical system make it possible to avoid optical aberrations, as well as to carry out high-quality focusing and scaling. The device is equipped with 2 contact boards (immersion and cross-polarized).



**Fig. 1.** Digital dermatoscope VEOS DS3

Dermatoscope (trichoscope) irefly DE330T (fig. 2) has an optical magnification up to 165x; digital up to 495x. Allows you to take pictures with a maximum resolution of 2 mps (1600 x 1200). Equipped with a three-layer glass - 650 nm. and a built-in polarizer with 12 gradations. There is the possibility of video recording. The backlight is represented by a system of 8 ultra-bright LEDs with adjustable brightness.

The device has a size of 13x3.6 cm. The diameter of the chamber is 4 cm.



**Fig. 2.** Dermatoscope (trichoscope) irefly DE330T

The DELTA 20 dermatoscope (fig. 3) has a color rendering coefficient  $CRI > 87$ . The color rendering system is represented by 4 LEDs. Two LEDs can be turned off for side lighting.

The optics of the device allows a 10-16-fold increase; undistorted all over the plane. The adjustable eyepiece has individual focusing with a correction range from  $-6$  to  $+6$  diopters.



**Fig. 3.** Dermatoscope DELTA 20

The Eurolight D30 dermatoscope (fig. 4) has a contact glass with a diameter of 25 mm, a backlight system with an illumination intensity (12,000 Lux) with a service life of up to 50,000 hours, focusing range: from  $-6$  to  $+3.5$  D, tenfold optical zoom, scale for early detection of pigmentation changes in the skin.



**Fig. 4.** Dermatoscope Eurolight D30

Visual analysis of the medical image allows the doctor to make a preliminary conclusion about the condition of the skin in a specific period of the disease. However, this method of obtaining information does not allow to extract the entirety of the data necessary to clarify the diagnosis and predict the further development of the disease. Methods of digital processing and analysis of dermatological images based on instrumental methods of data recording allow constructing an objective picture of the course of the disease, which allows the clinician to reasonably choose a strategy for further treatment of a patient with AD with a minimal subjective factor.

Purpose of work. The aim of the work is to develop an objective method for assessing the condition of the skin with AD based on numerical analysis of images of affected skin areas.

### Materials and methods

Studies of children with AD were conducted at the Department of Propaedeutics of Pediatrics No. 2 of KhNMU.

All patients and their parents voluntarily consented to participate in the study.

Among the children there are 5 girls, 5 boys. Children age - from 2 to 12 years.

The researchers collected an anamnesis and described the initial dermatological status of patients. Clinical monitoring involved determining the severity of the following symptoms: skin edema, erythema, papular elements, excoriation, itching, dryness.

Patients received systemic therapy, which included taking antihistamines. Outwardly, basic therapy with emollients and anti-inflammatory therapy with corticosteroids were used.

The dynamics of the skin process was evaluated on the 3rd, 14th, 17th and 28th day of treatment.

A comprehensive assessment was performed using the SCORAD index (Scoring of Atopic Dermatitis - Atopic Dermatitis Scale) [5].

The criteria for the effectiveness of therapy was the reduction or disappearance of dryness and signs of skin inflammation.

The condition of patients on the background of the therapy was evaluated: as a clinical recovery - full resolution of the skin inflammatory process; significant improvement - a decrease in the SCORAD index by 75% compared to the original data; improvement - a decrease in the SCORAD index by 25-50%; no change - decrease in the SCORAD index by less than 25% or no change.

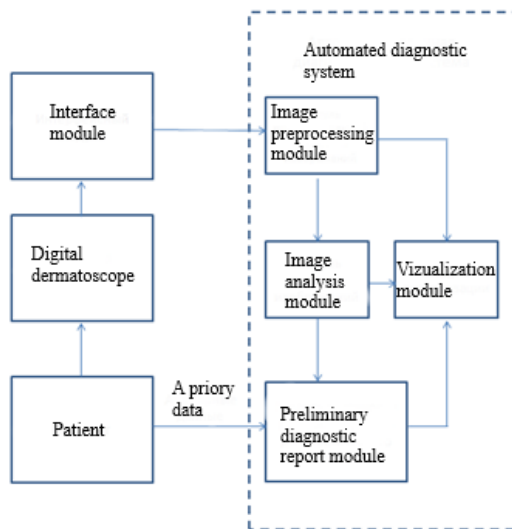
The images were recorded using a digital video dermatoscope UM039 with optical magnification up to 200 times [7], the resolution of the receiving matrix was  $2880 \times 1800$  image elements, equipped with a built-in block of adjustable LED lighting, a tripod and a rotary 3-inch display. The images were captured on a microSD card with subsequent transfer of data to the database on the computer.

The appearance of the device and an example of a diagnostic video dermatoscopic image are shown in fig. 5 and fig. 7 (a - e), respectively.



**Fig. 5.** Digital videodermatoscope UM039

The automated diagnostic system for processing and analyzing dermatoscopic information is presented in fig. 6.



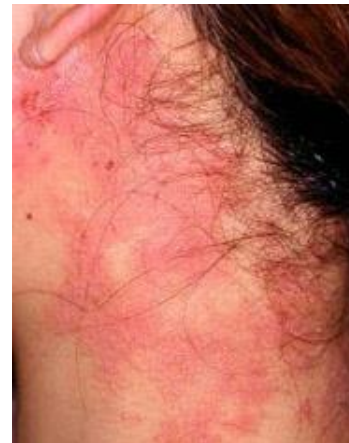**Fig. 6.** Automated diagnostic system for processing and analysis of dermatoscopic information

As a device for recording graphic information, a digital video dermatoscope UM039 was used; the interface module, which is a means of transmitting information to the database, can be implemented in the form of wired or wireless channels for transmitting information. The information preprocessing module includes means for monitoring data entered by a doctor for their correctness and consistency, as well as algorithms for eliminating image defects and improving its quality (methods for suppressing noisy components, correcting brightness and contrast). The image analysis module includes algorithms for evaluating color components and image segmentation. The preliminary diagnostic conclusion module includes various data classification algorithms.

The main research material. The article examined cases typical of the studied patient groups.

Clinical case 1. The patient is 8 years old. Registered by a dermatologist about ATD fig. 7. On examination, against the background of minor erythema, a few papular elements were noted in the neck fig. 8.

For the studied dermatoscopic images, the average values of the brightness channels in the RGB color model of the table were obtained 1.



**Fig. 7.** Localization of AtD lesions



**Fig. 8.** Localization of ATD manifestations for clinical case No. 1: a) skin condition on the third day of the examination; b) skin condition on the fourteenth day of the examination; c) skin condition on the seventeenth day of the examination; d) skin condition twenty-eighth day of examination

**Table 1.** The values of the brightness channels of the RGB color model, the studied images

N fig. channel	1	2	3	4	1 normal
R	249.7958	248.0176	241.3805	248.4456	240.786
G	170.9561	142.7206	157.2449	160.5349	154.344
B	168.7385	134.5160	135.6566	138.7161	138.76

Given (according to the data in table 1) the low visibility when displaying changes in color coordinates in the RGB space when observing the color of the skin surface during ATD in dynamics, it is advisable to switch to the HSV color space to study color changes using the perceptual color model.

For analysis, the images were converted to the HSV color model according to formulas (1–3) [8] and the values of the brightness channels of table 1 were determined.

$$V \leftarrow \max(R, G, B) \quad (1)$$

$$S \leftarrow \begin{cases} \frac{V - \min(R, G, B)}{V}, & \text{if } V \neq 0 \\ 0, & \text{elso} \end{cases} \quad (2)$$

$$H \leftarrow \begin{cases} \frac{60(G-B)}{S}, & \text{if } V = R \\ 120 + \frac{60(B-G)}{S}, & \text{if } V = G \\ 240 + \frac{60(R-G)}{S}, & \text{if } V = B \end{cases} \quad (3)$$

if  $H < 0$ , then  $H = H + 360$

**Table 2.** The values of the brightness channels HSV color model of the studied images

Figure	1	2	3	4	1 normal
H	355±4,2	1±4,2	18±4,2	19±4,2	18±3,6
S	50±4,6	47±3,2	45±3,4	40±2,2	40±2,8
V	93±9,3	99±8,1	94±8,7	99±7,2	98±8,5

From the analysis of color channels according to table 2 it is obvious that in patients with atopic dermatitis, the skin tone of the affected areas changes significantly when observed in dynamics. So, in the acute stage (at the beginning of treatment), the skin of the affected areas has a purple tint and, under the influence of therapy, shifts to the area of orange tones by an anticlockwise angle of about 20 degrees. The saturation of the skin in this case decreases in dynamics by 10 units. There were no significant differences in the brightness component of the images of the skin during AT in dynamics. It is also necessary to take into account individual anatomical variability and to bind to the patient's skin color in unaffected areas to increase the reliability of diagnosis under conditions of uncertainty [9, 10]. Additional methods aimed at analyzing video dermatoscopic images, for example, using Mueller-matrix transformations [11], can expand the possibilities of the proposed colorimetric diagnostics.

The method and system proposed in the work allow non-invasive instrumental diagnostics of the skin condition [12–18], which is very important in modern

dermatology and can be used to organize telemedicine consultations in conditions of self-isolation [19]. A promising approach based on an accurate assessment of the area of affected skin areas using 3D scanning of the patient's body can expand the capabilities of the method [20].

## Conclusion

Thus, we can conclude that in order to observe the condition of the skin during the treatment of AD in dynamics, one can apply the analysis of the color components of the affected areas on the HSV scale. This allows the specialist to intuitively observe the results of the therapy in an intuitive color space. The prospect of work is the development of a complete automated system for the comprehensive diagnosis of AtD and its clinical trials. Such a system will allow to form a preliminary diagnosis and determine the severity of the disease based on the evaluation of color channels of images of affected skin areas and additional diagnostic data.

## References

1. Wollenberg, A., Barbarot, S., Bieber, T. et al. (2018), "Wollenberg Consensus-based European guidelines for treatment of atopic eczema (atopic dermatitis) in adults and children: part I", *European Academy of Dermatology and Venereology*, No. 32 (5), P. 657–682. DOI: 10.1111/jdv.14891
2. Koszorú, K., Borza, J., Gulácsi, L., Sárdy, M. (2019), "Quality of Life in Patients with Atopic Dermatitis", *Medge dermatology*, No. 104 (03), P. 174–177.
3. Murashkin, N. N., Materikin, A. I., Ambarchjan, Je. T., Epishev, R. V. (2016), "Sovremennye predstavlenija o patogeneze i principah naruzhnoj terapii atopicheskogo dermatita u detej", *Current Pediatrics*, No. 6 (15), P. 584–589.
4. Illek, Ja. Ju., et al. (2007), "Diagnostika atopicheskogo dermatita u detej rannego vozrasta", *Vyatka Medical Bulletin*, No. 2, P. 83–92.
5. Kunz, Oranje, Labrèze, Stalder, Ring (1997), "Clinical validation and guidelines for the SCORAD index: consensus report of the European Task Force on Atopic Dermatitis", *Dermatology*, No. 195 (1), P. 10–19.
6. Trubicyn, A. A., Isaeva, O. A., Klimenko, V. A., Avrunin, O. G. (2019), "Instrumental methods of assessment of skin state at atopic dermatitis", *Science and Production*, No. 20, P. 180–187. DOI: doi.org/10.31498/2522-9990202019184898
7. Avrunin, O., Klimenko, V., Trubicyn, A., Isaeva, O. (2019), "Development of Automated System for Video Intermatoscopy", *Proceedings of the IX International Scientific and Practical Conference International Trends in Science and Technology*, Vol. 2, January 31, 2019, Warsaw, Poland, P. 6–9.

8. Nosova, Ya. Farouk, V., Avrunin, O. (2013), "Development of the method of express diagnostics of bacterial microflora of the nasal cavity", *Problems of information technologies*, Kherson, No. 13, P. 99–104.
9. Avrunin, O. G., Bodyansky, Ye. V., Kalashnyk, M. V., Semenez, V. V., Filatov V. O. (2018), *Modern intelligent technologies of functional medical diagnostics [Suchasni intelektual'ni tekhnolohiyi funktsional'noyi medychnoyi diahnostryky]*: Monograph, Kharkiv, NURE, 248 p. DOI: 10.30837/978-966-659-234-0.
10. Shhapov, P. F., Avrunin, O. G. (2011), "Poluchenie informacionnoj izbytochnosti v sistemah izmeritel'nogo kontrolja i diagnostiki izmeritel'nyh obektov", *Ukrainian Metrological Journal*, No. 1, P. 47–50. Pat. 109839 Ukraina, MPK G 01 N 21/00, G 01 N 21/39 (2006.01).
11. Bojchuk, T. M., Ushenko, O. G., Novakovska, O. Yu., Grygoryshyn, P. M. (2016), Sposib diagnostyky staniv dermy shkiry za dopomogyu analizu myuller-matrychnyx zobrazhen; zayavnyk Vyshhyj derzhavnyj navchalnyj zaklad Ukrayiny "Bukovynskij derzhavnyj medychnyj universytet", No. u201602401; zayavl. 12.03.2016; opubl. 12.09.2016, Byul. No. 17.
12. Makarenko, L. A. (2013), "Neinvazivnaja diagnostika v dermatologii", *Russian Journal of Skin and Sexually Transmitted Diseases*, No. 2, P. 40–45.
13. Dmytrenko, S. V., Stepanenko, V. I., Vernygorodskij, S. V., Nalizhytyj, A. A. Pat. 110303 Ukrayina, MPK A61B 8/08. Sposib dermatoskopichnoyi ocinky tyazhkosti ixtiozu; zayavnyk Vinnyczkyj nacionalnyj medychnyj universytet im. M. I. Pyrogoва. # a201412529; zayavl. 21.11.2014; opubl. 10.12.2015, Byul. # 23.
14. Kogan, B. G. (2013), "Atopichnyj dermatyt : akcent na bezpechnosti likuvannya", *Ukrainian Journal of Dermatology, Venerology, Cosmetology*, No. 1 (48), P. 81–89.
15. Zajnullina, O. N., Hismatullina, Z. R., Pechkurov, D. V. (2017), "Sovremennye metody ocenki sostojaniya kozhi pri atopicheskom dermatite u detej", *Allergology and Immunology in Pediatrics*, No. 4 (51), P. 4–9.
16. Isaeva, O. A., Avrunin, O. G. (2019), "Development of an automated system for video dermatoscopy", *Materials of the 23rd International Youth Forum. Vol. 1*, Kharkiv, KNUR, P. 165–166.
17. Rajpara, S. M., Botello, A. P., Townsend, J., Ormerod, A. D. (2009), "Systematic review of dermoscopy and digital dermoscopy", *Artificial Intelligence for the Diagnosis of Melanoma*, Br J Dermatol, No. 161 (3), P. 591–604.
18. Guitera, P., Menzies, S. W. (2011), "State of the art of diagnostic technology for early-stage melanoma", *Expert Rev Anticancer Ther*, No. 11 (5), P. 715–723.
19. Isaeva, O. A., Trubicin, A. A. (2020), "Vozmozhnosti telemedytsynskikh servisov dermatologii", *Materiali HH Vseukrains'koj naukovo-tehnichnoj konferencii molodih vchenih, aspirantiv ta studentiv "Stan, dosjagnennja i perspektivi informacijnih sistem i tehnologij"*, Ch. 2, Odesa, ONAHT, P. 51–53.
20. Isaieva, O. A., Avrunin, O. G. (2020), "Possibilities of application of 3D-Scanning in determining of damaged areas of skin", *Abstracts of X International Scientific and Practical Conference*, San Francisco, USA, P.139–142.

Received 23.04.2020

*Відомості про авторів / Сведения об авторах / About the Authors*

**Аврунін Олег Григорович** – доктор технічних наук, професор, Харківський національний університет радіоелектроніки, завідувач кафедри біомедичної інженерії, Харків, Україна; email: oleg.avrunin@nure.ua; ORCID: <https://orcid.org/0000-0002-6312-687X>.

**Аврунин Олег Григорьевич** – доктор технических наук, профессор, Харьковский национальный университет радиоэлектроники, заведующий кафедрой биомедицинской инженерии, Харьков, Украина.

**Avrunin Oleh** – Doctor of Sciences (Engineering), Professor, Kharkov National University of Radio Electronics, Head of the Department of Biomedical Engineering, Kharkiv, Ukraine.

**Трубіцин Олексій Олексійович** – Харківський національний університет радіоелектроніки, аспірант кафедри біомедичної інженерії, Харків, Україна; email: altr287@gmail.com; ORCID: [orcid.org/0000-0002-7581-1700](https://orcid.org/0000-0002-7581-1700).

**Трубицин Алексей Алексеевич** – Харьковский национальный университет радиоэлектроники, аспирант кафедры биомедицинской инженерии, Харьков, Украина.

**Trubicin Alexey** – Kharkov National University of Radio Electronics, Post-Graduate Student of the Department of Biomedical Engineering, Kharkiv, Ukraine.

**Ісаєва Ольга Андріївна** – Харківський національний університет радіоелектроніки, студентка кафедри біомедичної інженерії, Харків, Україна; email: olha.isaieva@nure.ua; ORCID: <https://orcid.org/0000-0001-7832-4695>

**Исаева Ольга Андреевна** – Харьковский национальный университет радиоэлектроники, студентка кафедры биомедицинской инженерии, Харьков, Украина.

**Isaeva Olga** – Kharkov National University of Radio Electronics, Student of the Department of Biomedical Engineering, Kharkiv, Ukraine.

**Клименко Вікторія Анатоліївна** – доктор медичних наук, професор, Харківський національний медичний університет, завідувач кафедрою пропедевтики педіатрії №2, Харків, Україна; email: klymenkoviktoria@gmail.com; ORCID: <http://orcid.org/0000-0002-6762-9650>.

**Клименко Виктория Анатольевна** – доктор медицинских наук, профессор, Харьковский национальный медицинский университет, заведующая кафедрой пропедевтики педиатрии №2, Харьков, Украина.

**Klymenko Viktoriia** – MD, Professor, Kharkiv National Medical University, Head of the Department of Fundamentals of Pediatrics No. 2, Kharkiv, Ukraine.

## МОЖЛИВОСТІ ОЦІНКИ ЕФЕКТИВНОСТІ ЛІКУВАННЯ АТОПІЧНОГО ДЕРМАТИТУ НА ОСНОВІ АНАЛІЗУ КОЛЬОРОВИХ ХАРАКТЕРИСТИК ВІДЕОДЕРМАТОСКОПІЧНИХ ЗОБРАЖЕНЬ

**Предметом** статті є дослідження кольорних характеристик відеодерматоскопічних зображень уражених ділянок шкіри дітей з atopічним дерматитом і розробка автоматизованої діагностичної системи обробки і аналізу дерматоскопічних знімків. **Метою** роботи є розробка об'єктивного методу оцінки стану шкіри дітей з atopічним дерматитом на основі чисельного аналізу зображень уражених ділянок шкіри. **Завданнями** роботи було збір анамнезу життя дітей з atopічним дерматитом, дослідження кольорних характеристик відеодерматоскопічних зображень уражених ділянок шкіри і подальша розробка автоматизованої діагностичної системи обробки і аналізу дерматоскопічної інформації. **Методи** дослідження. В ході проведених діагностичних обстежень дітей з atopічним дерматитом був зібраний анамнез життя і описаний вихідний дерматологічний статус пацієнтів. Комплексну оцінку ступеня тяжкості захворювання проводили за допомогою індексу SCORAD. Реєстрацію зображень проводили за допомогою цифрового відеодерматоскопу UM039 з оптичним збільшенням до 200 разів, дозволом сприймаємої матриці  $2880 \times 1800$  елементів зображення, оснащеним вбудованим блоком регульованого світлодіодного освітлення, штативом і поворотним 3-х дюймовим дисплеєм. Фіксація зображень виконувалася на карту microSD з подальшим перенесенням даних в базу на комп'ютері. Результати проведеного дослідження, на підставі отриманих даних, дозволили оцінити інтенсивність і динаміку запальних процесів уражених ділянок шкіри дітей з atopічним дерматитом і сформулювати принципи роботи автоматизованої діагностичної системи обробки і аналізу дерматоскопічних знімків. **Висновки.** В кінці дослідження автори приходять до висновку, що для спостереження за станом шкіри при лікуванні atopічного дерматиту можна застосовувати аналіз кольорних компонент уражених ділянок в шкалі HSV, що дає можливість фахівцеві інтуїтивно спостерігати за результатами проведеної терапії в природному для людського сприйняття кольорному просторі. Як перспективою розвитку роботи автори обґрунтовують передумови розробки завершеної автоматизованої системи комплексної діагностики atopічного дерматиту та її клінічного випробування. Подібна система може дозволити на основі оцінки кольорних каналів зображень уражених ділянок шкіри і додаткових діагностичних даних сформувати попередній діагноз і визначити ступінь тяжкості захворювання.

**Ключові слова:** atopія; дерматит; яскравість; HSV; колір.

## ВОЗМОЖНОСТИ ОЦЕНКИ ЭФФЕКТИВНОСТИ ЛЕЧЕНИЯ АТОПИЧЕСКОГО ДЕРМАТИТА НА ОСНОВЕ АНАЛИЗА ЦВЕТОВЫХ ХАРАКТЕРИСТИК ВИДЕОДЕРМАТОСКОПИЧЕСКИХ ИЗОБРАЖЕНИЙ

**Предметом** статьи является исследование цветовых характеристик видеодерматоскопических изображений пораженных участков кожи детей с atopическим дерматитом и разработка автоматизированной диагностической системы обработки и анализа дерматоскопических снимков. **Целью** работы является разработка объективного метода оценки состояния кожи детей с atopическим дерматитом на основе численного анализа изображений пораженных участков кожи. **Задачами** работы являлось сбор анамнеза жизни детей с atopическим дерматитом, исследование цветовых характеристик видеодерматоскопических изображений пораженных участков кожи и дальнейшая разработка автоматизированной диагностической системы обработки и анализа дерматоскопической информации. **Методы** исследования. В ходе проведенных диагностических обследований детей с atopическим дерматитом был собран анамнез жизни и описан исходный дерматологический статус пациентов. Комплексную оценку степени тяжести заболевания проводили с помощью индекса SCORAD. Регистрацию изображений проводили с помощью цифрового видеодерматоскопа UM039 с оптическим увеличением до 200 раз, разрешением воспринимающей матрицы  $2880 \times 1800$  элементов изображения, оснащенный встроенным блоком регулируемого светодиодного освещения, штативом и поворотным 3-х дюймовым дисплеем. Фиксация изображений выполнялась на карту microSD с последующим переносом данных в базу на компьютере. **Результаты** проведенного исследования, на основании полученных данных, позволили оценить интенсивность и динамику воспалительных процессов пораженных участков кожи детей с atopическим дерматитом и сформулировать принципы работы автоматизированной диагностической системы обработки и анализа дерматоскопических снимков. **Выводы.** В конце исследования авторы приходят к выводу, что для наблюдения за состоянием кожи при лечении atopического дерматита можно применять анализ цветовых компонент пораженных участков в шкале HSV, что дает возможность специалисту интуитивно наблюдать за результатами проводимой терапии в естественном для человеческого восприятия цветовом пространстве. В качестве перспектив развития работы авторы обосновывают предпосылки разработки завершеной автоматизированной системы комплексной диагностики atopического дерматита и ее клинического испытания. Подобная система может позволить на основе оценки цветовых каналов изображений пораженных участков кожи и дополнительных диагностических данных сформировать предварительный диагноз и определять степень тяжести заболевания.

**Ключевые слова:** atopія; дерматит; яркость; HSV; цвет.

### Бібліографічні описи / Bibliographic descriptions

Аврунін О. Г., Трубіцин О. О., Ісаєва О. А., Клименко В. А. Возможности оцінки ефективності лікування atopічного дерматиту на основі аналізу кольорових характеристик відеодерматоскопічних зображень. *Сучасний стан наукових досліджень та технологій в промисловості*. 2020. № 2 (12). С. 127–133. DOI: <https://doi.org/10.30837/2522-9818.2020.12.127>.

Avrunin, O., Trubitsin, A., Isaeva, O., Klymenko, V. (2020), "Possibilities for assessing the effectiveness of treatment of atopіc dermatitis based on an analysis of color characteristics of video dermatoscopic images", *Innovative Technologies and Scientific Solutions for Industries*, No. 2 (12), P. 127–133. DOI: <https://doi.org/10.30837/2522-9818.2020.12.127>.