

UDC [615.238:615.458:616.211:615.015.35]:57.084.1

DOI: 10.15587/2519-4798.2020.199597

SOME ASPECTS OF ENISAMIUM IODIDE NASAL SPRAY SAFETY: PRE-CLINICAL STUDY RESULTS

T. Zhulai, I. Zupanets, S. Shebeko, S. Zimin, K. Yampolska

Мета. Обґрунтування безпеки використання нового назального спрею з Енісаміумом Йодидом за результатами дослідження гострої місцевопоздражнювальної дії досліджуваного препарату одноразовому введенні у кон'юнктивальний мішок та носовий хід кролів.

Матеріали та методи. Енісаміум Йодид 10 мг/мл (назальний спрей) був об'єктом тестування. Референтним препаратом був 0,9 % розчин натрію хлориду. Для індукції експерименту використовували кролів породи Фландр (Фламандський Гігант) (2 групи, по 9 кролів у кожній групі). Об'єкти дослідження вводили одноразово в очні кон'юнктивальні мішки (0,01 мл) та носові ходи (0,1 мл) шляхом інстиляції. Очний огляд ми проводили в різні часові точки спостереження (через 1, 24, 48 та 72 години після введення препаратів). Назальна ендоскопія застосовувалася для контролю стану слизової оболонки порожнини носа на всіх стадіях дослідження (за 15 хвилин до, 1 годину та 24 години після інстиляції лікарських засобів) під загальною анестезією. Шкала оцінки використовувалася для об'єктивності результатів.

Результати. Загальний бал становив 0 балів у всіх групах у всі періоди часу спостереження за відповідною шкалою та шкалою оцінки слизової оболонки порожнини носа кролів за результатами ендоскопії носа. Це відповідає стану здорового ока та здорової слизової оболонки носа.

Висновки. Енісаміум Йодид 10 мг/мл (назальний спрей) при одноразовому введенні в кон'юнктивальний мішок та носовий хід кролів не виявляв ммисцевопоздражнювальної дії на кон'юнктиву ока та слизову порожнину носа у експериментальних тварин. Назальна ендоскопія може бути використана як інформативний візуальний метод у доклінічних дослідженнях

Ключові слова: гостра місцевопоздражнювальна дія, Енісаміум Йодид (назальний спрей), назальна ендоскопія, одноразове введення, релевантна шкала оцінки

Copyright © 2020, T. Zhulai, I. Zupanets, S. Shebeko, S. Zimin, K. Yampolska.

This is an open access article under the CC BY license (<http://creativecommons.org/licenses/by/4.0>).

1. Introduction

Rhinosinusitis (RS) is inflammation of the nasal sinuses and affects approximately 12 % of the population [1]. Acute rhinosinusitis (ARS) is an inflammation of the nasal cavity and nasal sinuses mucosa with sudden symptom onset and duration of all symptoms up to 12 weeks. ARS is characterized by a decrease of life quality of patients with the possible development of complication (chronic RS, orbital and intracranial complications, et al.) [1–3]. At the same time, orbital and intracranial complications are gradually increasing in severity and number [4]. In addition, ARS is a very common diagnosis, accounting for approximately 30 million primary care visits to the United States and requiring more than \$ 11 billion in health care costs annually [5]. ARS management is regulated by EPOS 2020 [6] and «Universal clinical protocol for primary, secondary (specialized) and tertiary (highly specialized) medical care. Acute rhinosinusitis» (Order of the Ministry of Health of Ukraine No. 85 2016) [7]. However, it should be noted that most drugs for pathogenic and symptomatic treatment of the different forms of ARS (viral, post-viral and bacterial ARS) have high-level evidence and strength of recommendations. There are glucocorticoids, fixed combinations of antihistamine, analgesics and decongestants, herbal drugs, acetylsalicylic acid and other NSAIDs. Most of these drugs are used orally with a systemic effect and therefore have a potential risk of side effect development. The use of drugs such as intranasal forms

of corticosteroids, despite the high-level evidence in the treatment of individual forms of ARS, is not rational in the treatment of viral ARS. The use of irrigation therapy with saline solutions of various concentrations based on sea or mineralized water, despite the presence of topical forms, will not always lead to a rapid decrease in all symptoms of ARS, for example, such as facial pain.

However, despite the presence of a large number of drugs for treatment of various ARS forms, the use of an intranasal dosage form ensures high compliance due to ease of use and high safety. The presence of a drug with various pharmacodynamic effects (anti-inflammatory and analgesic effects, antiviral and interferonogenic activity) in an intranasal dosage form can be effective.

A new nasal spray with Enisamium Iodide aqueous solution (N-methyl-4-benzylcarbamidopyridinium Iodide) original dosage form of a well-known pharmaceutical substance – has been developed by Farmak JSC (Ukraine). The anti-inflammatory action of Enisamium Iodide (EI) has been proved in the pre-clinical studies [8–10], potentially justifies high drug effectiveness in the nasal spray dosage form for ARS treatment. It causes a direct positive effect on the inflammation and swelling into the nasal cavity, paranasal sinuses, and sinus ostium. However, studying the safety of a medicinal product with a new route of administration is an integral component of creating a new drug or the scientific rationale for using an existing drug according to new indications.

The aim of the study to substantiate the safety using of the new nasal spray with anti-inflammatory action, which contains EI at a concentration of 10 mg/mL administered intranasally via study results of acute local drug-induced irritant action of the single-dose of the test object to eyes and nasal cavity mucosa. We developed the study design, which is shown in Fig. 1.

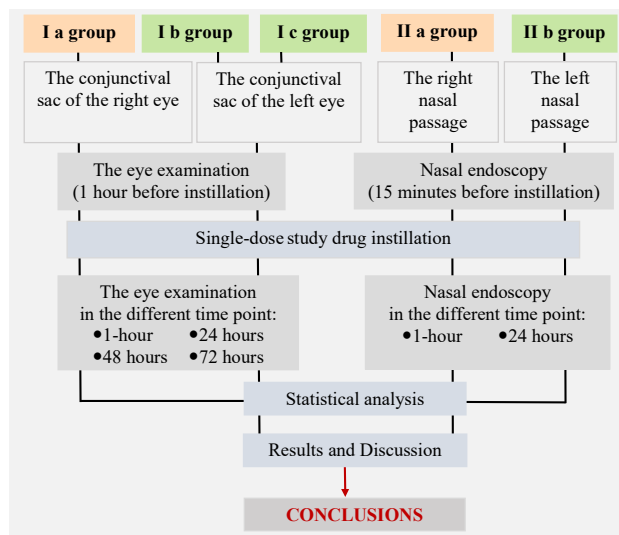


Fig. 1. Design of the pre-clinical study «Acute local drug-induced irritant action of the test objects in the single-dose to eyes and nasal cavity mucosa»:

Orange – the studied animal group where 0.9 % saline were instilled; Green – the studied animal group where Enisamium Iodide 10 mg/mL (nasal spray) were instilled.

2. Material and Methods

EI nasal spray (JSC Farmak, Ukraine) with an active substance concentration of 10 mg/mL was the test object. This concentration has been chosen considering the previous stage results of the of EI (nasal spray) pre-clinical studies [8–11]. The reference drug was 0.9 % saline.

Eighteen Flemish Giant rabbits of both sexes aged around 90–110 days weighing 2.5–3 kg were used to induce the experiment. Study of local drug-induced irritant action was conducted according to the methodological recommendations «Pre-clinical study of the local drug-induced irritant action» [12]. The baseline data related to all study groups are illustrated in Table 1.

The test animals were kept in the Central Scientific-Research Laboratory of the National University of Pharmacy following the sanitary standards and the required diet. All studies were conducted in compliance with the general ethical principles of animal experiments established by Directive 2010/63/EU concerning the protection of animals used for experimental and other scientific purposes [13]. The Bioethics Commission of the National University of Pharmacy (Kharkiv, Ukraine) approved study design (Protocol No 3 of 15 March 2017).

Intact controls were contralateral anatomical structures. These were right rabbit eyes and right rabbit nasal passages, respectively. All study objects were administered in an unchanged state into the eye conjunctival sacs and nasal passages using Biohit Proline fixed volume pipettor 200 µl with Biohite pipettor tips [14]. Before drug administration, rabbits were fixed in special boxes. Prior to the study object instillation, we examined both eyes and both nasal passages in all experimental groups.

The eye examination we performed 1 hour before instillation of the study objects for initial control of eye condition, as described in the methodological recommendations [12]. Observations were made through 1, 24, 48 and 72 h after drug administration (instillation of the study objects in single-dose into the conjunctival sac of the eyes). Local drug-induced irritant action on the eye mucous membranes was studied on the relevant scale of evaluation of the indicators: the state of the tissues around the eyes, including eyelids, the condition of the conjunctiva, blinking membrane, cornea and iris in each animal.

Nasal endoscopy was used for control of nasal cavity mucosa in all stages of study (15 minutes before instillation of the study objects into the nasal passage, 1-hour and 24 hours after drug instillation with digitally capturing). The procedure was performed under general anesthesia with Ketamine/Xylazine (35/5 mg/kg, intramuscularly [15]) using Karl Storz rhinoscopes (Germany): the one was diameter 4 mm, length 150 mm, 30° angle and the other was diameter 2.7 mm, length 110 mm, 0° angle. The pictures were digitally captured using the rhinoscope and then examined to reveal the pathological changes. The condition of the nasal cavity mucosa was evaluated according to the following nasal endoscopy parameters: swelling and hyperemia of the middle turbinate, amount and character of discharge into the nasal passage (Table 2).

Table 1

The distribution of experimental animals (¹n=18)

Animal groups		Study object	Single-dose	Route of administration
I group (n ² =9)	I a – intact control group (n ² =9)	0.9 % saline	0.01 mL	Instillation into the conjunctival sac of the right eye
	I b ³ (n ² =6)	Enisamium Iodide 10 mg/mL (nasal spray)	0.01 mL	Instillation into the conjunctival sac of the left eye
	I c ⁴ (n ² =3)			
II group (n ² =9)	II a	0.9 % saline	0.1 mL	Instillation into the right nasal passage
	II b	Enisamium Iodide 10 mg/mL (nasal spray)	0.1 mL	Instillation into the left nasal passage

Note: ¹n – total number of the experimental animals; ²n – number of the experimental animals in each groups; I b³ – the animals, which eyes were not washed after a single instillation of the test object; I c⁴ – the animals, which 20 seconds after a single instillation of the test object, the eyes were washed with water at room temperature for 1 minute

Table 2

The scale of the assessment of rabbit nasal cavity mucosa by nasal endoscopy results

Middle turbinate swelling	Middle turbinate hyperemia	The presence of discharge into the nasal passage	Discharge character	Points
No changes	No changes	Within normal limits	Mucous discharge	0
Mild swelling	Mild hyperemia	Presence of a small amount of discharge / Slight dryness	Watery discharge	1
Moderate swelling	Moderate hyperemia	Presence of moderate amount of discharge / Moderate dryness	Watery-hemorrhagic discharge	2
Significant swelling	Diffuse hyperemia	Presence of abundant discharge / Significant dryness	Hemorrhagic or purulent discharge	3

Statistical analysis of the results was performed using Kruskal-Wallis one-way analysis of variance and Mann-Whitney U test for a posteriori pairwise comparisons [16, 17]. Utilized computer software included IBM SPSS Statistics v. 22 (IBM Corp., USA) and MS Excel 2016 (Microsoft Corp., USA). The level of statistical significance was considered as $p < 0.05$.

3. Results

In the observation of animals after instillation of the studied objects, no changes in the animal behavior were observed, which could serve as signs of pain or discomfort. Signs of short-term blepharospasm (from 10 to 90 seconds) were observed in groups I a, I b and I c, which is most likely associated with the procedure of instilling the studied objects in the eye than with the properties of these drugs. These phenomena stopped on their own and did not require any additional treatment. In general, during of the eye examination at all-time points of observation, there were no signs of irritation. The eyes of all animals in I b and I c studied groups remained unchanged compared to the control eye (I a group) (Fig. 2). The cornea remained transparent without signs of turbidity; its surface was smooth and shiny. The iris of the left eye of the studied animals looked intact; a positive reaction to light was quick and full. None of the animals had erythema, edema and secretions (Fig. 2).

The total score on the relevant scale [12] was 0 points in all groups at all-time points, which corresponds to the condition of a healthy eye.

In studying of the acute local drug-induced irritant action of the test object single-dose on the nasal mucosa, the application of the studied drugs did not attract significant changes in the general condition and behavior of animals. The combination of drugs given by materials and methods (general anesthesia with Ketamine/Xylazine) led to the formation of sufficient depth and duration of drug sleep; however, all animals were in satisfactory condition, alert and active after its completion. General anesthesia created satisfactory conditions for nasal endoscopy conducting before the instillation of the studied objects and 1-hour after this instillation (this was the first and the second episode of general anesthesia). Repeated general anesthesia (24 hours after the studied object instillation) also did not cause any negative changes either in the general condition or in the behavior of the animals. Nasal endoscopy allowed an intravital objective assessment of

the condition of the nasal mucosa of experimental animals, significantly increased the possibility of an objective assessment, and allowed the material to be digitally captured for further analysis that is more thorough. In addition, a significant fact in favor of intravital nasal endoscopy is that this technique allows you to more closely follow modern bioethical standards for conducting experiments on animals, causing them the least possible harm.

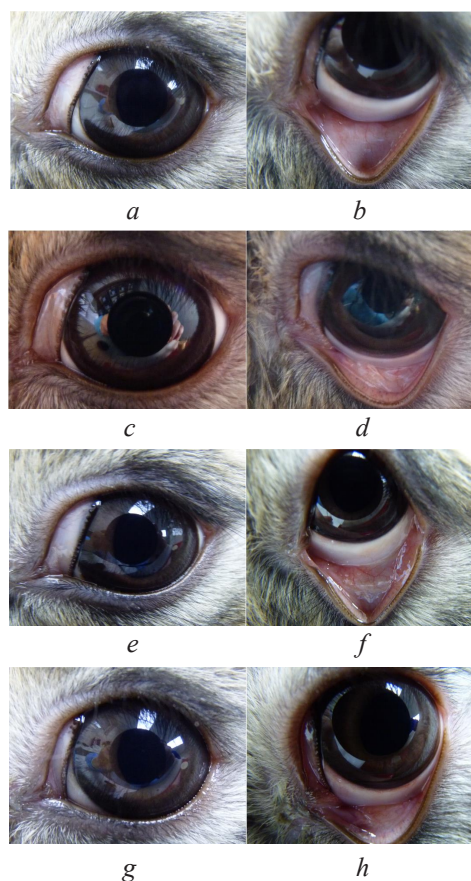


Fig. 2. Left eye condition of I b and I c groups in a different time point of observation (Enisamium Iodide 10 mg/mL (nasal spray) instillation into the conjunctival sac): a, b – in 1 hour; c, d – after 24 hours; e, f – after 48 hours; g, h – after 72 hours

Therefore, the results of nasal endoscopy of the right (intact) nasal passage in II a group (before, 1-hour and 24 hours after the studied object instillation) were as follows (Fig. 3):

- the nasal mucosa was pale pink;
- on the surface of the mucosa was a small amount of transparent mucous discharge;
- sometimes a vascular pattern was visualized, consisting of unexpanded and unconvoluted vessels that were not overfilled with blood;
- no areas of hyperemia or swelling were observed.

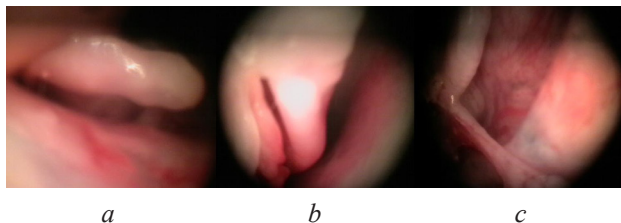


Fig. 3. Nasal endoscopy of the II a group in a different time point of observation (the right half of the nasal cavity, 0.9 % saline instillation):
a – before instillation; *b* – 1 hour after instillation;
c – 24 hours after instillation

The same rhinoscopic pattern was observed with nasal endoscopy of the left nasal passage in animals of group II b (Fig. 4):

- the nasal mucosa was pale pink with a small amount of transparent mucous discharge;
- the vascular pattern was unchanged;
- without signs of hyperemia or swelling.

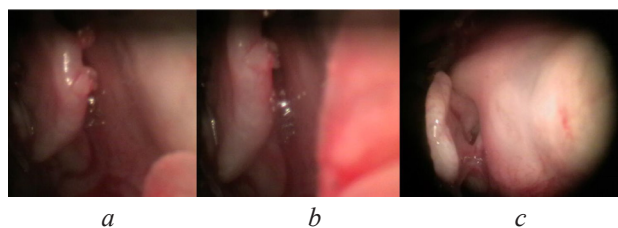


Fig. 4. Nasal endoscopy of the II b group in a different time observation point (the left half of the nasal cavity, Enisamium Iodide 10 mg/mL (nasal spray) instillation):
a – before instillation; *b* – 1 hour after instillation;
c – 24 hours after instillation

The total score was 0 points in both groups (II a and II b) at all-time points according to the scale of the assessment of rabbit nasal cavity mucosa by nasal endoscopy results (Table 2), which corresponds to the condition of a healthy nasal cavity mucosa.

4. Discussion

After statistical analysis of the total score on the relevant scale [12] of the comparative study results obtained we have not observed acute local drug-induced irritant action of the test objects in the single-dose instillation into the rabbit eye conjunctival sac. The total score was 0 in all groups at all-time points, which corresponds to the condition of a healthy eye. The absence of negative changes in the cornea, iris, conjunctiva and blinking membrane for 72 hours in a single-dose installation of the study objects in a conjunctival sac at a dose of 0.1 ml indicates the absence of the local drug-induced irritant

action of the Enisamium Iodide 10 mg/mL (nasal spray) on the test animal eyes.

After statistical analysis of the total score on the relevant scale (Table 2) of the comparative study results obtained we have not observed acute local drug-induced irritant action of the test objects in the single-dose instillation into the rabbit nasal passages. The total score was 0 points in both groups (II a and II b) at all-time points according to the scale of the assessment of rabbit nasal cavity mucosa by nasal endoscopy results (Table 2). Thus, it is possible to assume that the test object Enisamium Iodide 10 mg/mL (nasal spray) at the single-dose administration did not show local drug-induced irritant action on the rabbit nasal mucosa in our experiment.

However, it is worth noting that in the nasal rhinoscopy evaluation, we observed a single line hemorrhages of up to 3 mm in length on nasal mucosa into right and left nasal passages in some animals (four animals in II a group and three animals in II b group) (Fig. 3, 4). Probably, these phenomena are associated with the procedure of nasal endoscopy, during which it is impossible to completely avoid minor trauma to the nasal mucosa, but this does not affect the condition of the mucosa and animals in general.

Therefore, we can argue that nasal endoscopy is one of the most effective and safe methods of visual assessment in experimental rhinology and could be used in preclinical studies of new drugs.

Study limitations. However, studying of drug safety with a new route of administration is not limited to studying an acute local drug-induced irritant action. We have got good results of the pre-clinical studies [8–11] and clinical trial (phase I has been conducted as a single-centre, randomized, double-blinded, placebo-controlled clinical trial with dose-escalation – the study of local tolerance and safety of different doses with healthy volunteers). Despite this, we do not have enough data to make conclusion about the complete pharmacological profile of the Enisamium Iodide 10 mg/mL (nasal spray).

Prospects for further researches. We are planning to continue studying Enisamium Iodide 10 mg/mL (nasal spray) through preclinical studies and clinical trials. The preclinical study aims will be an in-depth study of Enisamium Iodide effectiveness in experimental RS. Clinical trials will aim to study the effectiveness and safety of EI in topical use in patients with acute rhinosinusitis. At all stages of research, we will plan to use nasal endoscopy, as the most informative visual method in experimental rhinology.

6. Conclusions

Test object Enisamium Iodide 10 mg/mL (nasal spray) has no local irritant effect on rabbit eye conjunctiva.

Test object Enisamium Iodide 10 mg/mL (nasal spray) has no local irritant effect on the rabbit nasal cavity mucosa.

It is possible to assume that Enisamium Iodide 10 mg/mL (nasal spray) does not have local irritant properties.

Enisamium Iodide 10 mg/mL (nasal spray) is a perspective object for further pre-clinical studies and clinical trials aiming to substantiate of its safety and effectiveness for ARS treatment as well as its implementation to the clinical practice.

Nasal endoscopy could be used in preclinical studies of new drugs as an informative visual method for assessment in experimental rhinology.

Acknowledgements

This work was supported by the grant «Pharmacological study of biologically active substances and medicines» (No 0114U000956, National University of Pharmacy).

Conflicts of interest

The authors declare no conflicts of interest.

References

1. Kwah, J. H., Peters, A. T. (2019). Nasal polyps and rhinosinusitis. *Allergy and Asthma Proceedings*, 40 (6), 380–384. doi: <http://doi.org/10.2500/aap.2019.40.4252>
2. Çelik, M., Kaya, K. H., Yegin, Y. et. al. (2019). Anatomical Factors in Children with Orbital Complications Due to Acute Rhinosinusitis. *Iranian Journal of Otorhinolaryngology*, 31 (106), 289–295.
3. Sella, G. C. P., Tamashiro, E., Anselmo-Lima, W. T., Valera, F. C. P. (2017). Relation between chronic rhinosinusitis and gastroesophageal reflux in adults: systematic review. *Brazilian Journal of Otorhinolaryngology*, 83 (3), 356–363. doi: <http://doi.org/10.1016/j.bjorl.2016.05.012>
4. Mengko, S. K., Soemantri, R. D., Juniati, S. H. (2018). Correlation Between Objective Evaluation Result of Nasal Congestion and Life Quality in Patients with Acute Rhinosinusitis. *Indian Journal of Otolaryngology and Head & Neck Surgery*, 71 (3), 1929–1934. doi: <http://doi.org/10.1007/s12070-018-1333-4>
5. De Boer, D. L., Kwon, E. (2019). *Acute Sinusitis*. StatPearls. Treasure Island (FL): StatPearls Publishing. Available at: <https://www.ncbi.nlm.nih.gov/books/NBK547701/>
6. Fokkens, W. J., Lund, V. J., Mullol, J. et. al. (2012). European position paper on rhinosinusitis and nasal polyps. *Rhinology*, 50 (23), 1–298.
7. Ministry of Health of Ukraine. Universal clinical protocol for primary, secondary (specialized) and tertiary (highly specialized) medical care. *Acute rhinosinusitis* (2016). Order of the Ministry of Health of Ukraine, 85, 17–24.
8. Zhulay, T. S., Shebeko, S. K., Zupanets, I. A. (2017). The study of the dose-dependent antiexudative effect of a new anti-inflammatory nasal spray. *Clinical pharmacy*, 21 (4), 11–16. doi: <http://doi.org/10.24959/cphj.17.1446>
9. Zhulai, T. S. (2018). The preclinical study of a new nasal spray with the anti-inflammatory properties: the effect on the leukotriene-induced inflammation. *Clinical pharmacy*, 22 (4), 27–33. doi: <http://doi.org/10.24959/cphj.18.1473>
10. Zhulai, T., Shebeko, S., Goy, A. (2018). Perspectives for use of the new nasal spray with anti-inflammatory action in treatment of acute rhinosinusitis. *Rhinology*, 56 (27), 585.
11. Zupanets, I. A., Popovich, V. I., Zhulai, T. S., Volosovets, O. P., Shebeko, S. K., Kryvopustov, S. P. et. al. (2019). Pharmaceutical care of patients in acute rhinosinusitis treatment. *Kharkiv: Golden pages*, 36.
12. Kovalenko, V. M., Tsytkun, O. G. (2007). *Preclinical study of the local drug-induced irritant action*. Kyiv: St. Pharm. Center, 13–31.
13. Parliament, European & Council, European (2010). DIRECTIVE 2010/63/EU on the protection of animals used for scientific purposes. *EU Official Journal*. L276. Available at: <https://eur-lex.europa.eu/LexUriServ/LexUriServ.do?uri=OJ:L:2010:276:0033:0079:EN:PDF>
14. Turner, P. V., Pekow, C., Vasbinder, M. A., Brabb, T. (2001). Administration of Substances to Laboratory Animals: Equipment Considerations, Vehicle Selection, and Solute Preparation. *Journal of the American Association for Laboratory Animal Science*, 50 (5), 614–627.
15. Flecknell, P. A. (2016). *Laboratory Animal Anesthesia*. Oxford: Academic Press, 350. doi: <http://doi.org/10.1016/c2013-0-13494-0>
16. Islam, M. A., Al-Shiha, A. (2018). *Foundations of Biostatistics*. Springer Nature Singapore Ltd. doi: <http://doi.org/10.1007/978-981-10-8627-4>
17. Quirk, T. J., Quirk, M. H., Horton, H. F. (2016). *Excel 2016 for Biological and Life Sciences Statistics: A Guide to Solving Practical Problems*. Springer International Publishing Switzerland. doi: <http://doi.org/10.1007/978-3-319-39489-3>

Received date 23.01.2020

Accepted date 17.02.2020

Published date 31.03.2020

Zhulai Tetiana, Assistant, Department of Clinical Pharmacology and clinical Pharmacy, National University of Pharmacy, Pushkinska str., 53, Kharkiv, Ukraine, 61002;
Otolaryngologist, Municipal non-profit enterprise “City Clinical Hospital No. 30” of Kharkiv City Council, Gudanova str., 5/7, Kharkiv, Ukraine, 61024
E-mail: tszhulay2910@gmail.com

Zupanets Igor, MD, Professor, Head of Department, Department of Clinical Pharmacology and clinical Pharmacy, National University of Pharmacy, Pushkinska str., 53, Kharkiv, Ukraine, 61002
E-mail: igorzupanets@gmail.com

Shebeko Sergii, PhD, Associate Professor, Department of Clinical Pharmacology and Clinical Pharmacy, National University of Pharmacy, Pushkinska str., 53, Kharkiv, Ukraine, 61002
E-mail: shebekosk@gmail.com

Zimin Stanislav, PhD, Assistant, Department of Clinical Pharmacology and Clinical Pharmacy, National University of Pharmacy, Pushkinska str., 53, Kharkiv, Ukraine, 61002
E-mail: zimstasmich@gmail.com

Yampolska Kateryna, Otolaryngologist, Municipal non-profit enterprise “City Clinical Hospital No. 30” of Kharkiv City Council, Gudanova str., 5/7, Kharkiv, Ukraine, 61024;
PhD, Department of Otolaryngology and Pediatric Otolaryngology, Kharkiv Medical Academy of Post-graduate Education, Amosova str., 58, Kharkiv, Ukraine, 61176
E-mail: ekatyampolskaya@gmail.com

УДК: 618.3:615.851:159.922.73-053.3:619.39-084

DOI: 10.15587/2519-4798.2020.199848

РІВЕНЬ ПРИВ'ЯЗАНОСТІ ДО ПЛОДУ У ЖІНОК ІЗ ЗАГРОЗОЮ ПЕРЕДЧАСНИХ ПОЛОГІВ НА ІІІ ТРИМЕСТРІ ВАГІТНОСТІ ТА ПСИХОМОТОРНИЙ РОЗВИТОК ДИТИНИ ПЕРШОГО РОКУ ЖИТТЯ У СВІТЛІ ВЗАЄМОДІЇ В СИСТЕМІ «МАТИ – ДИТИНА»

Н. В. Гринько

Мета роботи – вивчення рівня прив'язаності до плоду жінок із загрозою передчасних пологів на ІІІ триместрі вагітності та психомоторного розвитку дитини першого року життя.

Матеріали і методи. У дослідження було включено 150 вагітних на ІІІ триместрі вагітності (23–37 тижнів), та їх чоловіків. Із них основну групу склали 120 жінок з із загрозою передчасних пологів на останньому триместрі вагітності (ОГ). Групу порівняння становили 30 жінок з фізіологічним перебігом вагітності (ГП).

Результати та обговорення. Встановлено, що у жінок ОГ рівень прив'язаності матері до плоду становив $71,0 \pm 1,0$ (порушення прив'язаності), а у жінок ГП $51,0 \pm 2,0$ (достатній рівень прив'язаності). Оцінка психомоторного розвитку дитини протягом першого року життя довела існування тенденції щодо відставання його показників у дітей матерів ОГ (після другого обстеження ОГК) порівняно з немовлятами жінок ГП та ОГТ протягом усіх періодів спостереження ($p < 0,05$). Така різниця показників психомоторного розвитку спостерігалася вже на третьому обстеженні: рівень розвитку дітей матерів ГП був достовірно вищим, ніж у жінок ОГ. На четвертому обстеженні діти матерів ОГТ ($29,0 \pm 0,2$) продемонстрували кращі показники психомоторного розвитку, ніж немовлята жінок ОГК ($27,5 \pm 0,3$), проте нижчі, ніж у ГП ($29,4 \pm 0,1$). У подальшому рівень психомоторного розвитку дітей ГП та ОГТ практично зрівнявся на відміну від показників дітей ОГК ($28,1 \pm 0,4$), що були нижчими, ніж в інших групах. При досягненні малюками віку одного року найкращий рівень психомоторного розвитку продемонстрували діти матерів ОГТ ($29,2 \pm 0,3$), практично однакові результати були у дітей ГП ($29,1 \pm 0,3$), а показники дітей ОГК були нижчими ($28,5 \pm 0,2$).

Висновки. Серед негативних факторів, що провокують формування порушення діадичної взаємодії, провідними є психологічна неготовність до материнства та низький рівень прив'язаності до плоду жінок із загрозою передчасних пологів на ІІІ триместрі вагітності

Ключові слова: загроза передчасних пологів, рівень прив'язаності матері до плоду, психомоторний розвиток дитини

Copyright © 2020, N. Grinko.

This is an open access article under the CC BY license (<http://creativecommons.org/licenses/by/4.0>).

1. Вступ

Різноманітними дослідженнями накопичено багато інформації по визначну роль перинатально-

го періоду у формуванні особистості та життєвого шляху людини. Загалом, можна констатувати, що найбільш вагоме значення для розвитку Еґо має