

UDC 617-089.844

DOI: 10.15587/2519-4798.2021.237931

IMPLEMENTATION OF MINI-INVASIVE METHODS OF BILE DRAINAGE IN THE TREATMENT OF BLASTOMATOUS MECHANICAL JAUNDICE

Stanislav Kosulin

Tumor diseases of the BPDZ (biliopancreatoduodenal zone) occupy one of the leading places among the causes of disability and mortality of the population, both according to global and domestic statistics, while in 85–90 % of cases, patients with distal tumor biliary obstruction are detected. The most common symptom of malignant tumors of periampullary localization is OJ (obstructive jaundice), which is found in 86–95 % of patients and becomes the first manifestation of the disease in 65–70 % of cases.

Purpose. Optimization of surgical treatment in surgically incurable patients with obstructive blastomatous jaundice.

Materials and methods. The study was clinical in nature, it was carried out on the basis of CCH №17 (Kharkov, Ukraine) and the State Institution “Institute of General and Emergency Surgery named after V. I. Zaitsev National Academy of Medical Sciences of Ukraine”) and consisted of two stages. The main task of the first stage was a retrospective assessment of the results of antegrade and retrograde minimally invasive interventions performed in the period from 2006 to 2011 in 122 patients. The main objective of the second stage of the study was to assess the results of surgical treatment of 75 patients with blastomatous breast, who were treated from 2012 to 2019, using the developed treatment algorithm.

Results. At the first stage of the study, the effectiveness of endoscopic transpapillary and transhepatic biliary excretion methods in patients with distal malignant obstruction of the gastrointestinal tract was compared, for which patients who underwent minimally invasive interventions were divided into two subgroups: group A (63 observations) biliary excretion, and in group B (59 observations) as biliary decompression antegrade percutaneous-transhepatic methods of drainage of biliary ways were applied.

Endoscopic transpapillary surgery showed itself to be, not inferior to open surgery in effectiveness of biliary decompression, instead it has a number of advantages, such as low trauma, relative safety, low complication and mortality.

Conclusions. The developed algorithm of bile excretion in incurable patients with blastomatous MF allowed to minimize the number of postoperative complications to 4.0 %, to avoid the development of transient hyperamylasemia and postmanipulation pancreatitis. Endoscopic retrograde methods of RV prosthetics as the final stage of surgical treatment in this category of patients have certain advantages over antegrade methods of external drainage, primarily due to the preservation of the natural passage of bile in the duodenum and better adaptation and tolerability by patients

Keywords: blastomatous mechanical jaundice, minimally invasive treatment, antegrade and retrograde methods of choledochal drainage

© The Author(s) 2021

This is an open access article under the Creative Commons CC BY license

How to cite:

Kosulin, S. (2021). Implementation of mini-invasive methods of bile drainage in the treatment of blastomatous mechanical jaundice. ScienceRise: Medical Science, 4 (43), 22–28. doi: <http://doi.org/10.15587/2519-4798.2021.237931>

1. Introduction

Tumors of the biliopancreatoduodenal zone (BPDZ) amount for about 15 % of all malignant neoplasms of the gastrointestinal tract or about 5–6 % of all malignant tumors detected in Ukraine. Tumor diseases of BPDZ occupy one of the leading places among the causes of disability and mortality of the population, both according to global and state statistics where 85–90 % of the cases belong to patients with distal tumor biliary obstruction [1].

Distal obstruction of the BPDZ is caused by the so-called periampullary tumors which are including malignant neoplasms of the distal common bile duct (CBD),

the head of the pancreas, and the major duodenal papilla (MDP). All these tumors are alike due to a close anatomical location, frequent occurrence of obstructive jaundice (OJ) syndrome, common clinical symptoms and similarity of treatment tactics [2, 3]. The differences are associated with the prognosis of the disease and variations of surgical operations at the initial stages of the tumor process. Undoubtedly, only surgery is the only radical method of treating tumors of this localization. However, due to the difficulties of early diagnosis, the resectability of neoplasms remains extremely low: pancreatic head cancer – 10–15 %, extrahepatic bile duct cancer – 15–30 %, BPDZ cancer – 40–70 % [4]. In case of extensive local

invasion or presence of distant metastases the method of surgical treatment, complications rate and life expectancy do not differ significantly [5].

The most common symptom of malignant tumors of periampullary localization is the OJ taking place in 86–95 % of cases and appears as the first manifestation of the disease in 65–70 % of cases. It usually takes from 3 to 12 months from the tumor growth to the clinical manifestation when the yellowing of skin alerts a patient and results in seeking of medical help. Depending on the primary tumor localization the rate of OJ detected during the initial treatment varies up to: 37.4 % in case of pancreatic head cancer, distal CBD cancer – 90 %, BPDZ cancer – 64 % [6].

The problem of restoring an adequate passage of bile in various malignant diseases of the BPDZ organs remains quite relevant to the present time [7, 8].

Tactical approaches and decisions in the treatment of patients with malignant neoplasms of BPDZ complicated OJ have undergone certain changes in the last few decades. Surgical treatment performed on patients with blastomatous jaundice result in large number of complications, and mortality can reach 15–60 % [9]. The unsatisfactory results of general surgical treatment performed in any OJ complicated cases dictate the need to perform a two-stage treatment where decompression of BPDZ in order to restore the natural bile passage.

Recent advances in curating such group of patients are associated, first of all, with the wider implementation and application in clinical practice of modern minimally invasive treatment technologies. Modern techniques of preoperative biliary decompression have significantly expanded the possibilities of performing complex high-tech radical surgical operations [5, 7]. However, a fairly rapid invasion of the tumor process into many nearby vital organs and vessels leads to a frequent reason for the impossibility of performing a radical operation. Due to the fact that the operability of tumors of this localization does not exceed 15–17 % while the use of palliative general surgical methods of biliary decompression results in a high rate of complications and mortality, it is of considerable interest to determine the algorithm for performing minimally invasive methods of biliary drainage among patients of given category [10].

Purpose. Surgical treatment optimization in cases of surgically incurable obstructive blastomatous jaundice.

2. Materials and methods

The study was clinical in nature, carried out on the basis of the 17th City Hospital (Kharkov, Ukraine) and State Institution "Institute of General and Emergency Surgery named after V. T. Zaitsev («National Academy of Medical Sciences of Ukraine») and consisted of two stages. The main task of the first stage was a retrospective results' assessment of performed antegrade and retrograde minimally invasive interventions in the period from 2006 to 2011 in 122 patients. The main objective of the second stage of the study was to evaluate the results of surgical treatment of 75 patients with blastomatous OJ, treated in the period from 2012 to 2019 using the developed treatment algorithm.

In order to include patients in the study we formed a system of criteria that made it possible to select a ho-

mogeneous group of patients. The patients signed an agreement form composed according to WMA Declaration of Helsinki approved by the department of «oncological surgery, radiotherapy and palliative care» 17.02.06 protocol No. 11.

Study inclusion criteria: patients over the age of 18; the presence of OJ (the level of bilirubin is more than 50 $\mu\text{mol/l}$); the duration of OJ does not exceed 14 days; the need for nutritional support; the need of effective bile excretion; the patient's agreement to the proposed complex of examination and treatment.

The exclusion criteria from the study were the following indicators: contraindications to surgical treatment (Child-Pugh type C); severe hemorrhagic disorders; acute infectious pathology (active hepatitis B and C); duodenal obstruction; the presence of other active onco-pathology and blood diseases; pregnancy; uncontrolled hypertension or high risk of uncontrolled arrhythmia; mental illness, drug or alcohol addiction; lack of patient agreement to the proposed complex of examination and treatment.

In accordance with the work objectives, a comparative assessment of the results of treatment of two groups of patients with stenosis of the terminal section of the common bile duct (CBD) of tumor genesis, accompanied by acute OJ, was carried out. The average age of patients at the first stage of the study was (70.2 \pm 1.2) years, at the second – (70.1 \pm 1.5) years. The patients analyzed in both study periods were comparable in terms of sex and age, the nature and distribution of the underlying and concomitant pathology and nosology that caused the development of OJ.

The information obtained was systematized using a specially developed case patient card, which contained all the parameters that could be used for analysis: gender, age of the patient, the presence of concomitant pathology, complaints, medical history, basic and additional laboratory and instrumental examination methods, the type of surgical operations, lengths of operations, stages of treatment, complications, duration of treatment, mortality.

To select the surgical tactics for treating patients, we used the classification proposed by E. I. Galperin et al.

The diagnosis was made on the basis of physical examination data, anamnesis data, results of clinical and biochemical analyzes, data of instrumental research methods. The main screening method of instrumental diagnostics was transabdominal ultrasound (TAUS), which made it possible to confirm the obstructive nature of jaundice, determine the degree of biliary hypertension, the level of biliary obstruction, and identify focal lesions of the parenchymal organs of the abdominal cavity and retroperitoneal space. The study was carried out on diagnostic devices SDU-400 from Shimadzu, Logic-500 from General Electric, and Aspen from Acuson.

To ensure the current X-ray control over the manipulation, an arkoscope was used, and as the latter, a mobile X-ray deck "Diasonics" (USA) with digital image processing, operating in continuous and pulsed modes, with the possibility of sequential accumulation of up to 64 obtained images, was used.

Punctures of the bile ducts and gallbladder were performed under X-ray sonoscopic control and were per-

formed with echotyped needles 19–22 G with a mandrel. Punctures were performed under local anesthesia (in the absence of contraindications) of 0.5 % novocaine solution, under strictly aseptic conditions.

All diagnostic and therapeutic manipulations under X-ray sonoscopic control were performed in the Department of X-ray surgical methods of diagnosis and treatment.

Endoscopic examinations were carried out on the basis of the Department of Endoscopic Diagnostic and Treatment Methods using Olympus apparatus JF 1T-20, GIF-E, PQ-20 (Japan) and a set of endoscopic instruments. Visualization of the resulting image was carried out using a video information system of the company "Olimpus" and a DVD recorder JVC (Japan).

Endoscopic retrograde cholangiopancreatography (ERCP) and endoscopic papillosphincterotomy (EPST) were performed using an Olympus UES-10 high-frequency electric generator and a set of papillotomes.

Computed tomography (CT) was performed to clarify the localization, local spread of the tumor, to determine distant metastases and free fluid in the abdominal cavity on a Hi Speed LX/I spiral computed tomograph, General Electric (USA).

Magnetic resonance imaging (MRI) was performed on a Signa Contour 0.5T GJM MS apparatus from General Electric (USA) in T1 and T2 modes.

Statistical data processing was performed using statistical packages MedStat v.4.1. The p-value tested using following formula $\chi^2 = \sum((o-e)^2/e)$, where «o» – observed results, «e» – expected results.

3. Results

At the first stage of the study, we compared the efficacy of endoscopic transpapillary and percutaneous transhepatic methods of bile drainage in patients with distal obstruction of BPDZ caused by malignant neoplasms, for which patients who underwent minimally invasive interventions were divided into two groups: subgroup A (63 observations) consisted of patients, who underwent various endoscopic retrograde methods of biliary drainage, and subgroup B (59 observations) where antegrade percutaneous-transhepatic methods of biliary drainage were used as biliary decompression.

In total, group A underwent 78 endoscopic transpapillary interventions. One-stage endoscopic treatment was performed in 49 patients (77.8 %), two-stage intervention was performed in 13 patients (20.6 %), a three-stage approach was required in 1 person (1.6 %).

Selective cannulation and contrast enhancement of CBD in this group was performed in 60 patients (95.2 %). For the purpose of manipulative access to the biliary tract, cannulation EPST was performed in 24 patients (38.1 %), atypical – in 18 clinical cases (28.5 %), and a combination of atypical and cannulated papillotomy – in 14 cases (22.2 %). In 7 cases (11.1 %) EPST was not performed, which in 3 cases was associated with a previously performed papillotomy according to anamnesis. In total, cannulation EPST was used in 22 cases (34.9 %), since it seemed mandatory to perform it with the simultaneous installation of several polymer stents, as well as in patients without severe hyperbilirubinemia and coagulopathy in order to prevent the development of acute post-manipulation pancreatitis.

As the primary endoscopic method of bile drainage, 27 patients (42.9 %) of group A underwent nasobiliary drainage (NBD), and 36 patients (57.1 %) underwent endobiliary stenting. In 12 cases, the primary implementation of nasobiliary drainage was determined by the need for dosed decompression in patients with acute cholangitis clinic or CBD debridement in order to prevent early obturation of stents with microliths in surgically incurable patients. After stopping the phenomena of cholangitis and complete sanitation of the biliary ducts, he underwent endobiliary prosthetics as the final palliative method of treatment. In the case of BMD tumors, the advantage in choosing an endoprosthesis was given to polymer stents of the Pigtail or Tannenbaum type.

External drainage of hepaticoholedochus was performed in 59 (46.5 %) patients, while in 21 (35.6 %) patients of this group with a class C OJ, this method was the final stage of treatment. Percutaneous transhepatic cholangiostomy was performed in 34 patients, percutaneous transhepatic cholecystostomy – 9 cases, external-internal drainage – 18, prosthetics – 18 patients. Direct fistulocholangiography, as a method to clarify level and nature of the bile excretion block, was performed in order to control the effectiveness of the manipulation.

In general, in group B, the cholangiostomy position was stable in 32 (54.2 %), relatively stable – in 24 (39.0 %), unstable – in 4 (6.8 %) patients. In 2 (3.4 %) cases: after percutaneous transhepatic cholecystostomy and in case with unstable drainage position dislocation of the cholangiostomy requiring CBD draining reiteration was noted. No intra-abdominal complications noted during the study.

Immediate results of antegrade and retrograde methods of biliary excretion assessment was carried out according to following indicators: the baseline bilirubinemia level, number of patients with severe concomitant pathology, and the causes of distal CBD obstruction.

Comparison of patients of subgroups A and B in terms of the severity of hyperbilirubinemia at the time of admission to the hospital is shown in Fig. 1.

It should be noted that in the extremely serious condition of the patient and the presence of certain conditions for performing the intervention (pronounced dilatation of the intrahepatic ducts, the absence of a large amount of ascitic fluid in the abdominal cavity, "convenient ultrasound path"), the method of choosing biliary decompression was an external percutaneous transhepatic cholecystostomy under local anesthesia.

Antegrade drainage methods were reliably more often used in patients with a critical level of hyperbilirubinemia (more than 300 $\mu\text{mol/l}$ detected upon admission to the hospital ($p=0.0078$)). Retrograde decompression significantly prevailed in the groups with relatively mild jaundice – up to 100 $\mu\text{mol/l}$ ($p < 0,0001$).

Both groups were statistically homogeneous in terms of the number of detected cases of pancreatic and BPDZ cancer; MDP cancer occurred significantly more frequently in subgroup A than in subgroup B; however, tactically, retrograde decompression was used in incurable patients. Effective decompression in subgroup A was observed in 57 patients (90.5 %), antegrade methods of CBD drainage were effective in 55 patients (93.2 %).

After retrograde interventions in the early postoperative period complication developed in 3 cases

(5.3 %), after antegrade interventions – in 4 clinical cases (7.2 %).

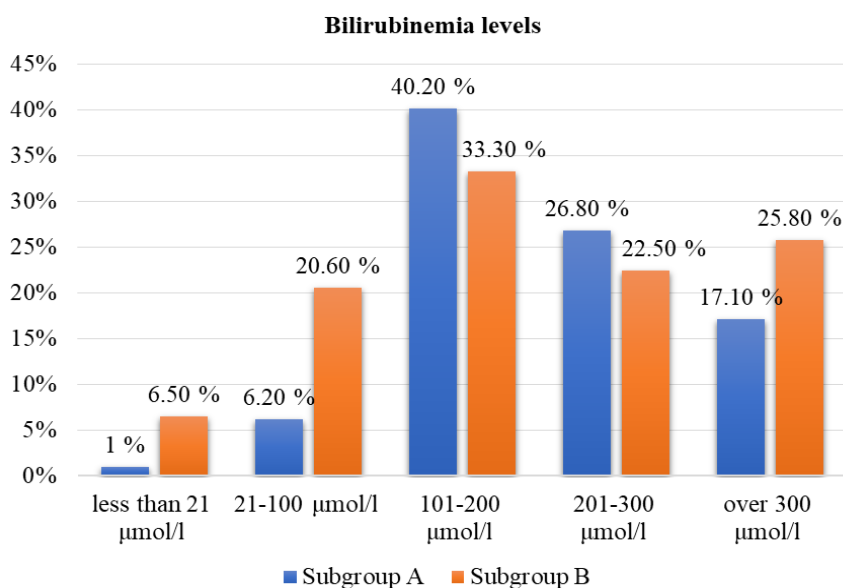


Fig. 1. Bilirubinemia levels in patients of A (n=63) and B (n=59) subgroups

Acute postoperative pancreatitis after performing transapillary techniques was observed in two patients which resulted in the need of transferring external-internal drainage to external drainage in postoperative period. One patient after an antegrade endoprosthesis implantation on the second day had a lethal outcome due to fulminant form of acute destructive pancreatitis. One patient underwent a drainage replacement, sanitation laparoscopy and drainage of the abdominal cavity. One patient died, which accounted for 1.6 % of observations.

In one case (1.8 %), percutaneous external cholangiostomy was complicated by bile leakage from the liver parenchyma and the formation of an abdominal biloma, which required an ultrasound-guided drainage of the abdominal cavity. Specific complications of antegrade drainage methods such as hemobilia followed by the biliary tree or gallbladder tamponade development, were observed in two cases (3.6 %) in the analyzed group and were resolved conservatively with hemostatic therapy and drainage sanitation. Infectious complications after antegrade decompression methods in the form of cholangitis and the formation of cholangiogenic abscesses in the liver on basis of acute obstructive cholangitis were detected in one patient (1.8 %).

After antegrade interventions, there were two deaths (3.4 %) that were not associated with the occurrence of complications after antegrade decompression. The cause of death in patients admitted to the clinic with obstruction of BPDZ by tumors of the pancreas and the distal common bile duct, in one case was the progression of the main disease despite successfully performed external bile duct drainage, and in one case - pulmonary embolism.

Comparative analysis of the closest results of retrograde and antegrade decompression in patients

with distal obstruction of the BPDZ of malignant etiology is presented in table. 1. Data analysis shows that in terms of the effectiveness of decompression, as well as the proportion of complications and mortality, antegrade and retrograde methods of minimally invasive decompression in patients with distal tumor obstruction of the BPDZ do not have statistically significant differences ($p > 0.05$).

Transient hyperamylasemia after antegrade interventions occurred only in 6 cases (10.9 %), after transapillary interventions – 28.1 %, which was statistically significantly higher ($p < 0.0001$). Acute post-manipulation pancreatitis after transapillary retrograde interventions complicated the postoperative period in 4.8 % of cases.

Late complications after antegrade interventions in the form of drainage migrations or obturations with recurrent OJ and an increase in cholangitis were detected in 10 patients (15.9 %). In all these cases, the choice of the method of treatment was for minimally invasive antegrade retraining or retrograde endoscopic interventions. Other complications of the posthospital period after, as a rule, external drainage of the venous drainage system were acute kidney pathology, water-electrolyte disturbances, coagulopathy against the background of hepatic dysfunction. In most cases, this was associated with migration or obstruction of drainages, non-compliance by patients with recommendations for the return of bile per os. All this led to the fact that in the group of patients with antegrade drainage the period of preparation for the next stage of treatment was on average 10–14 days longer than in the group with retrograde decompression.

We have developed an algorithm for the surgical treatment of incurable patients with a blastomatous jaundice (Fig. 2).

Table 1

Postoperative lethality comparison					
Intervention effectiveness	Subgroup A (n=57)		Subgroup B (n=55)		Statistical difference (Yates's correction for continuity)
	abs.	%	abs.	%	
Gallbladder access efficacy	59	93.6	58	98.3	0.003
Gallbladder draining efficacy	51	89.5	55	93.2	0.003
Surgical interventions` postoperative complications, mortality					
	Group A (n=63)		Group B (n=59)		χ^2 criteria)
	abs.	%	abs.	%	
Bleeding	–	–	1	1.7	0.6754
Biloma of abdominal cavity	–	–	1	1.7	0.1680
Mild acute pancreatitis	2	3.2	–	–	0.5949
Severe acute pancreatitis (including pancreonecrosis)	1	1.6	–	–	
Infectious complications	–	–	1	1.7	0.5949
Haemobilia	–	–	2	3.4	0.5949
Total:	3	4.8	4	6.8	0.5871
Mortality	1	1.6	–	–	0.6980
Surgical interventions` indirect postoperative complications, mortality					
Pulmonary embolism		0	1	1.7	0.1680
Disease progression		0.7	1	1.7	0.5309
Total mortality	1	1.6	2	3.4	0.5816

Note: * – the statistically significant difference when $p < 0.05$

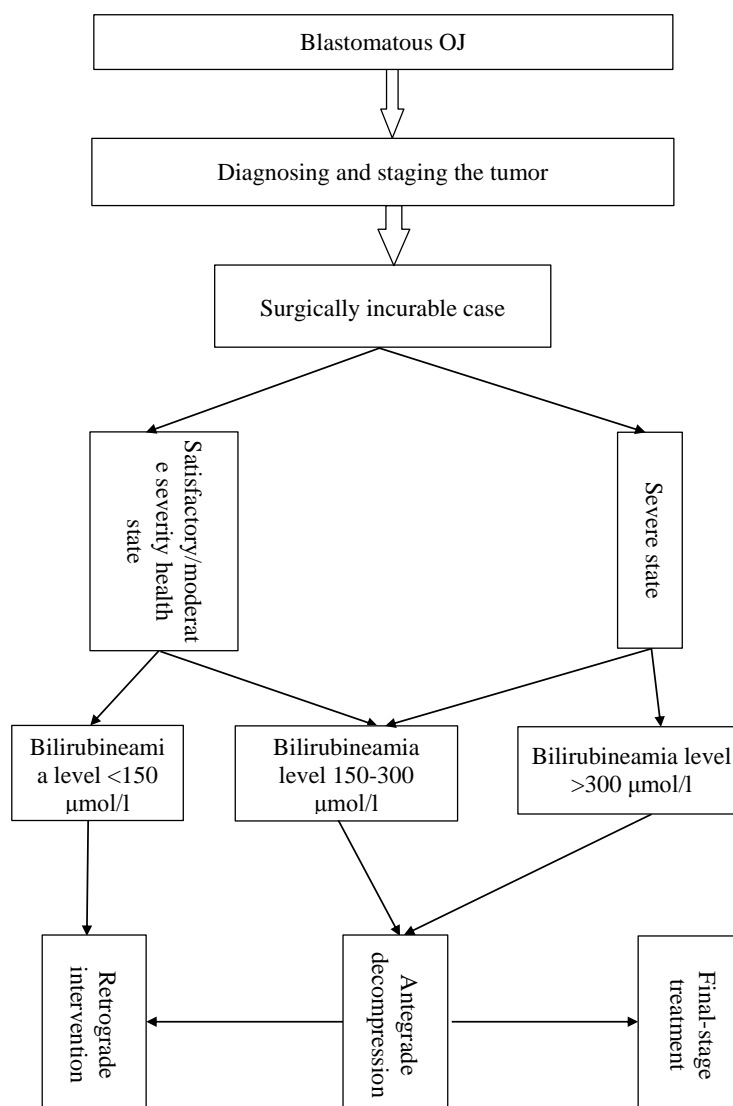


Fig. 2. Minimally invasive treatment algorithm of incurable patients with blastomatous jaundice

According to the developed algorithm for minimally invasive treatment of incurable patients with blastomatous jaundice in the most severe patients with a high (more than 150 $\mu\text{mol/l}$) bilirubinemia level, antegrade techniques are performed as the first stage as early as possible from the moment of admission as the first step of bile drainage, after patient's condition stabilization and preoperative preparation in a planned manner. – retrograde methods.

At the second stage of the study, transapillary techniques as the first and main stage were performed in 9 (12.0 %) cases; in 8 cases – 9 (10.7 %), in 7 (9.3 %) cases as the first stage – NBD followed by endobiliary prosthetics. In 13 (17.3 %) cases, in the most severe patients with a high anesthetic risk, percutaneous transhepatic cholangio and choledochostomy were performed as the final treatment. Antegrade gallbladder prosthetic drainage performed only in 4 (5.3 %) patients. In the remaining 54.7 % (41 patients), bile diversion was performed in two stages according to the algorithm.

In general, in 3 (4.0 %) cases, the position of the external drainage was unstable, which required re-drainage of the hepaticoholedochus. Intra-abdominal complications were not observed.

Antegrade bile diversion methods were effective in 100 % of cases, no repeated interventions were required.

Transient hyperamylasemia was observed in 9 (12 %) patients, while the postoperative period in none of the cases was complicated by pancreatitis and post-manipulation pancreatic necrosis.

In one (1.3 %) observation, the postoperative period was complicated by hemobilia, and in 2 (2.6 %) cases, the postoperative period was complicated by the development of cholangitis. The total number of postoperative complications was 4.0 %. During the hospital period, 2 patients died (2.6 %), the causes of death in one case were pulmonary embolism and one patient died due to the main disease progression.

4. Discussion

Endoscopic transapillary surgery in the presence of distal obstruction of the BPDZ of malignant genesis is not just an alternative to surgical interventions, but in combination with antegrade decompression is the method of choice in this group of severe cancer patients. Minimally invasive methods, not inferior in the effectiveness of biliary decompression, have a number of advantages, such as low trauma, relative safety, low incidence of complications and mortality [10].

The choice of minimally invasive biliary decompression method should be determined on the basis of further patient management tactics. As the final palliative method for the treatment of malignant strictures of the distal common bile duct, endoscopic retrograde methods

of BV prosthetics have certain advantages over antegrade methods of external drainage, primarily associated with the preservation of the natural passage of bile in the duodenum and better adaptation and tolerance on the part of patients.

At the same time, patients with installed biliary stents need active monitoring in order to timely detect violations of the bile outflow, perform sanitation and restenting bile tracts in order to prevent the development of cholangiogenic purulent complications.

Research limitations. Unlike isolated obstructive jaundice among otherwise healthy patients with no extra accompanying diseases and/or complications, blastomatous jaundice indicates severe BPDZ cancer cases, where jaundice is acting as a symptom, more than a direct threat. According to patients state and health in general, where, in some cases, first steps of miniinvasive treatment such as antegrade and retrograde drainage happen to be the final stage treatment with no more surgical interventions possible, statistical results of implemented methods differ within the framework of the research as well as the data used in referenced researches. According to this further, more thorough research still need to be held.

Prospects for further research. According to the mentioned restrictions of the research the collected data has further use both for practical application of implemented methods of miniinvasive treatment as well as theoretical statistics analysis for later comparison of upcoming if be continued researches.

5. Conclusions

The developed algorithm of bile drainage in incurable patients with blastomatous jaundice allowed to minimize the number of postoperative complications up to 4.0 % while Antegrade bile diversion methods were effective in 100 % of cases, no repeated interventions were required. To avoid the development of transient hyperamylasemia and post-manipulation pancreatitis. Endoscopic retrograde methods of bile duct prosthetic drainage as the final stage of surgical treatment in this category of patients have certain advantages over antegrade methods of external drainage: the preservation of the natural passage of bile in the duodenum and better adaptation and tolerance on the part of patients, primarily associated with the preservation of the natural passage of bile in the duodenum and better adaptation and tolerance on the part of patients.

Conflicts of interest

The authors declare that they have no conflicts of interest.

Financing

The study was performed without financial support.

References

1. Lupaltsov, V. Y. (2013). Sovremennoe sostoianye y perspektivy otechestvennoi pankreatologiy. Naukovyi Zhurnal MOZ Ukrainy, 1 (2), 37–46.
2. Budzinskiy, S. A., Shapovalyants, S. G., Fedorov, E. D., Mylnikov, A. G., Bakhtiozina, D. V. (2014). Sovremennye vozmozhnosti endoskopicheskogo retrogradnogo protezirovaniya zhelchnykh protokov v razreshenii mekhanicheskoy zheltukhi pri zlokachestvennykh opukholyakh organov pankreatobiliarnoy zony. Rossiyskiy zhurnal gastroenterologii, gepatologii, koloproktologii, 24 (5), 11–21.

3. Giovannini, M., Caillol, F., Monges, G., Poizat, F., Lemaistre, A.-I., Pujol, B. et. al. (2016). Endoscopic ultrasound-guided needle-based confocal laser endomicroscopy in solid pancreatic masses. *Endoscopy*, 48 (10), 892–898. doi: <http://doi.org/10.1055/s-0042-112573>
4. Nychytailo, M. Yu., Ohorodnyk, P. V., Deinychenko, A. H., Boiko, O. H., Khrystiuk, D. I., Shalkovska, H. I., Kycha, H. M. (2012). Algorithm of differential and topical diagnosis of obturationjaundice and miniinvasive correction of the main bile divertingpathways passability. *Klinichna khirurgiia*, 2, 5–10.
5. Teterin, Y. S., Tigiev, L. R., Yartsev, P. A., Stepan, E. V., Rogal, M. L., Kulikov, Y. D. (2021). Management of obstructive jaundice in patients with neoplasms of the major duodenal papilla. *Khirurgiya. Zhurnal Im. N. I. Pirogova*, 7, 49–56. doi: <http://doi.org/10.17116/hirurgia202107149>
6. Dumonceau, J.-M., Tringali, A., Papanikolaou, I., Blero, D., Mangiavillano, B., Schmidt, A. et. al. (2018). Endoscopic biliary stenting: indications, choice of stents, and results: European Society of Gastrointestinal Endoscopy (ESGE) Clinical Guideline – Updated October 2017. *Endoscopy*, 50 (9), 910–930. doi: <http://doi.org/10.1055/a-0659-9864>
7. Park, Y. J., Kang, D. H. (2013). Endoscopic drainage in patients with inoperable hilar cholangiocarcinoma. *The Korean Journal of Internal Medicine*, 28 (1), 8–18. doi: <http://doi.org/10.3904/kjim.2013.28.1.8>
8. Duan, F., Cui, L., Bai, Y., Li, X., Yan, J., Liu, X. (2017). Comparison of efficacy and complications of endoscopic and percutaneous biliary drainage in malignant obstructive jaundice: a systematic review and meta-analysis. *Cancer Imaging*, 17 (1). doi: <http://doi.org/10.1186/s40644-017-0129-1>
9. Shabunin, A. V., Lebedev, S. S., Tavobilov, M. M., Bagatelia, Z. A., Grekov, D. N., Karpov, A. A., Afanasieva, V. A. (2021). Preoperative biliary drainage for malignant biliary obstruction: to drain or not to drain? And if drain, in what way? *Khirurgiya. Zhurnal Im. N. I. Pirogova*, (6), 101–105. doi: <http://doi.org/10.17116/hirurgia2021051101>
10. Shahrokni, A., Saif, M. W. (2013). Metastatic pancreatic cancer: the dilemma of quality vs. quantity of life. *Journal of the pancreas*, 14 (4), 391–394. doi: <http://doi.org/10.6092/1590-8577/1663>

Received date 04.05.2021

Accepted date 08.06.2021

Published date 30.07.2021

Stanislav Kosulin, Department of Oncological Surgery, Radiotherapy and Palliative Care, Kharkiv Medical Academy of Postgraduate Education, Amosova str., 58, Kharkiv, Ukraine, 61176
E-mail: kosulinmd@gmail.com