

UDC 615.254:615.453.6:615.014.21

DOI: 10.15587/2519-4852.2023.286723

## STUDY OF PHARMACOLOGICAL ACTIVITY OF DRY EXTRACT OF SAKHALIN WILLOW SHOOTS AGAINST THE BACKGROUND OF EXPERIMENTAL THROMBOPHLEBITIS

Liudmyla Maloshtan, Kateryna Artemova, Nataliia Borodina, Oleksandr Kukhtenko

**The aim.** The objective of the research was to study the pharmacological activity of dry extract of Sakhalin willow shoots – DEWS against the background of experimental thrombophlebitis.

**Materials and methods.** Dry extract of Sakhalin willow shoots (DEWS) was the object matter of the present research and served as a therapeutic and prophylactic agent. In the experiment conducted, rabbits weighing 2.0–2.5 kg were used. The animals were divided into three groups. Group 1 was a control group; group 2 were animals that had been intragastrically injected with DEWS at a dose of 30 mg/kg prior to modelling thrombophlebitis; group 3 similarly received Eskuvit 20 mg/kg as a reference drug – pills (JSC Halychpharm, Ukraine). The dose for animals was recalculated, taking into account body weight according to the Rybolovlev method.

Experimental thrombophlebitis was caused by injecting an intravenous solution of 2 % lugol at a dose of 0.1 ml into the marginal vein of the ear. Statistical data processing was carried out using the Statistica for Windows 11.0 program based on variance analysis for repeated measurement data using the Mann-Whitney criteria at a probability level of  $p < 0.05$ .

**Results.** Against the background of the development of experimental thrombophlebitis in rabbits, the development of thrombosis of the ear vein and the inflammatory process of adjacent tissues were observed. The inflammatory process was accompanied by pronounced hyperemia and oedema. Prophylactic administration of DEWS for 6 days contributed to a decrease in the inflammatory process already on the 5<sup>th</sup> day of observation. The area of the injured area was 20 % smaller than in the control pathology group. The therapeutic and prophylactic effect of herbal medicine can be explained by the content of flavonoids and salicylates in its composition. Eskuvit showed a less pronounced thrombolytic effect in terms of its influence on thrombosis and thrombolysis.

**Conclusions.** The administration of DEWS in the therapeutic and prophylactic regimen at a dose of 30 mg/kg has a pronounced anti-inflammatory, thrombolytic and venoprotective effect in experimental peripheral venous thrombophlebitis in rabbits. The results of the studies obtained allow us to recommend DEWS as a promising venoprotective agent with thrombolytic activity

**Keywords:** dry extract of Sakhalin willow shoots, experimental thrombophlebitis, inflammatory process, pharmacological activity, rabbits

### How to cite:

Maloshtan, L., Artemova, K., Borodina, N., Kukhtenko, O. (2023). Study of pharmacological activity of dry extract of sakhalin willow shoots against the background of experimental thrombophlebitis. ScienceRise: Pharmaceutical Science, 4 (44), 97–103. doi: <http://doi.org/10.15587/2519-4852.2023.286723>

© The Author(s) 2023

This is an open access article under the Creative Commons CC BY license hydrate

### 1. Introduction

Thrombophlebitis is an acute inflammatory disease of the veins accompanied by the formation of blood clots inside the vascular bed and inflammation of the soft tissues surrounding the vein. At the same time, there is a violation of the structure of the vascular endothelium and a slowdown in blood flow, which leads to increased activity of the procoagulant and platelet links of the homeostasis system and, as a consequence, to thrombosis [1, 2].

Amongst the causes of this pathology may also be cardiovascular insufficiency, excess weight, prolonged standing and others [3]. This leads to risk factors, as a result of which there is a systemic decrease in the tone of the venous wall due to insufficient intake of angioprotectors, including herbal ones – phenolic compounds, flavonoids, ascorbic acid, etc. [4, 5].

Strengthening the vascular wall, increasing its elasticity, and reducing permeability improves venous blood flow and eliminates the main symptoms of venous insufficiency, such as swelling and a feeling of heaviness in the legs [6, 7].

Complexes of biologically active substances (BAS) have a number of undeniable advantages within the theory of varicose veins and thrombophlebitis. The absence of actual side effects on the body allows for the long-term use of herbal medicines in the complex therapy of vascular pathology [8, 9].

Therefore, the study of new herbal medicines that can make up for the lack of natural BAS and provide for a comprehensive therapeutic and preventive effect in vascular diseases is an urgent task.

The shoots of *Salix sachalinensis* F. Schmidt are a new source of medicinal plant material for producing

phytopreparations with a predictable raw material base. Schmidt, harvested from 'energy plantations' [10].

Willows are one of the largest genera of tree species in temperate climates. It is believed that there are about 350–370 species worldwide. Of these, 23–25 species naturally grow in Ukraine. Willows are distributed from alpine uplands to semi-deserts, deserts, and forest tundra and due to their biological stability, powerful photosynthesis apparatus and root system, resistance to adverse factors, ability to easily propagate vegetatively, develop intensively, form a number of generations, the relative longevity, ability to grow on lands not suitable for agriculture, they undoubtedly occupy one of the first places amongst other energy plants suitable for cultivation in Ukraine [11, 12].

At the Institute of Agriculture of Western Polissia of the National Academy of Agrarian Sciences of Ukraine, which is located in the village of Shubkov of the Rivnenskyi district, the Rivne Region, Ukraine, experimental plantations were laid and research work on the study of cultivation efficiency and productivity of energy crops is being conducted. The newly established nursery makes it possible to annually sell almost 5 million seedlings of 'energy willow' which can be planted on an industrial plantation of 300–400 hectares.

According to an expert assessment of Roman Shevchuk, the Head of the Laboratory of Fodder Production and Bioenergy Raw Materials, it is possible to harvest from 10 to 15 tons of dry mass per year from one hectare of energy willow and under favourable soil and climate conditions the yield increases to 25–30 tons. This is 14 times more productive than traditional forest plantations. Willow biomass can be harvested every year.

In the spring of 2012, within the framework of a regional programme, the Institute of Agriculture of Western Polissia of the National Academy of Agrarian Sciences of Ukraine sold about 800 thousand seedlings to establish plantations in Kostopilskyi, Dubrovetskyi, Rakitnivskyi, Vladimiretskyi, and Bereznivskyi districts on an area of 26 hectares. In addition, the public organization 'Rivne Centre for Market Research' implemented the project 'Establishment of Energy Willow Bioenergy Park' in the village of Bereg, Dubnenskyi district. There is a created plantation on an area of 10 hectares [13].

Previously, the Department of Pharmacognosy of the National University of Pharmacy studied the anatomical structure of *Salix sachalinensis* F. Schmidt. cormus, as well as the leaf ultrastructure and microscopic diagnostic features of the shoots of *Salix sachalinensis* F. Schmidt [10].

The complex of active substances contained in the dry extract of Sakhalin willow shoots includes salicylates, phenolic compounds, flavonoids, trace elements [10, 14, 15].

According to the literature, biological substances of Sakhalin willow exhibit anti-inflammatory, analgesic, venoprotective effects (reduce swelling in the venous part of the capillaries, improve lymph outflow and venous circulation, have a capillary-strengthening effect) [16–19].

The salicylates, flavonoids, and vitamin C contained in the extract are powerful natural antioxidants.

By stimulating nitrogen metabolism and participating in protein synthesis, salicylic acid in combination with dihydroquercetin has a directed vasoconstrictive effect, enhances capillary blood flow, reduces the risk of increased thrombosis and promotes vascular antispasmodic activity [20, 21].

**The research objective** was to study the pharmacological activity of dry extract of Sakhalin willow shoots – DEWS against the background of experimental thrombophlebitis.

## 2. Planning (methodology) of the research

One of the stages of preclinical research of a new phytoextract is the study of its pharmacodynamic properties, as a result of which it is possible to evaluate the spectrum of activities of this phytoextract and its advantages over existing drugs.

To achieve the goals set, we have developed a research algorithm that consists of the following stages:

- substantiation of the composition of dry extract of Sakhalin willow shoots (DEWS) as a thrombolytic and anti-inflammatory agent, since it contains salicylates (5 %) and flavonoids (5 %) the salicylates, flavonoids, and vitamin C contained in the extract are powerful natural antioxidants. By stimulating nitrogen metabolism and participating in protein synthesis, salicylic acid in combination with dihydroquercetin has a directed vasoconstrictive effect, enhances capillary blood flow, reduces the risk of increased thrombosis and promotes vascular antispasmodic activity [20, 21];

- selection of a reference drug and its administration and DEWS in a preventive mode. As a reference drug, the anti-inflammatory agent Eskuvit was used, which reduces vascular permeability, increases the tone of the venous wall, reduces peripheral oedema and trophic damage to the walls of venous vessels, and is also a herbal medicine [22];

- modelling of experimental thrombophlebitis. Previously, we have studied and published the pharmacodynamic properties of DEWS [18], namely anti-inflammatory, venotonic, and analgesic activity; it is advisable to study thrombolytic activity, which is one of the main complications of varicose veins on the model of experimental thrombophlebitis;

- conducting histological studies to confirm this pathology;

- establishment of thrombolytic, anti-inflammatory activity of DEWS in comparison with a reference drug on the model of experimental thrombophlebitis.

## 3. Materials and methods

The study was conducted on the basis of the Educational and Scientific Training Center of Biomedical Disciplines of the National University of Pharmacy (Kharkiv) from 2019 to 2021. All stages of the study were conducted in accordance with Directive 2010/63/EU of the European Parliament and of the Council of the European Union of September 22, 2010, «On the protection of animals used for scientific purposes» (Protocol of the Bioethics Commission No. 2 of November 4, 2019)

The extract was obtained according to the previously described technology from the raw material *Salix sachalinensis* F. Schmidt, which was harvested at the experimental 'energy plantation' of the Institute of Agriculture of Western Polissia of the National Academy of Agrarian Sciences of Ukraine (Shubkov village, the Rivne Region, Ukraine).

Raw material samples of *Salix sachalinensis* F. Schmidt were obtained with the assistance of Liudmyla Iakiva Lukashchuk, Deputy Director for Research of the Institute of Agriculture of Western Polissia of the National Academy of Agrarian Sciences of Ukraine.

The shoots of *Salix sachalinensis* F. Schmidt were collected from at least ten different plants, and a composite sample was formed, which was subsequently used to prepare extracts and conduct phytochemical, morphological, and anatomical studies and determine the purity of the raw material. Tops of shoots (40–50 cm long), including leaves and stems, were cut from willow plants and dried. Samples of plant material were dried at room temperature for 10 days, and the dried plant material was stored in well-sealed bags (paper or cloth) at room temperature before analysis. Herbarium samples and raw plant material of the Verbaceae family species that were used in our research are stored at the Department of Pharmacognosy, National University of Pharmacy (Kharkiv).

The object matter of the research was dry extract of Sakhalin willow shoots (DEWS) obtained according to the general scheme: air-dry raw materials, crushed to the size of particles passing through a sieve with a hole diameter of 3–5 mm, were placed in an extractor; extracted with 60 % ethyl alcohol (in the ratio of raw materials-extractant 1:10), taking into account the extractant absorption coefficient, at 90 °C for 2 hours. The operation was repeated 2 times; the third extraction was carried out with hot water until the BAS was completely extracted from the raw material. The obtained extracts were evaporated and dried in a vacuum evaporation apparatus at a temperature of 80 °C and a pressure of 80–87 kPa to a dry extract.

The resulting dry extract is a brown powder, loose, non-hygroscopic, with an odour, in which phenolic compounds were determined by high-performance liquid chromatography (HPLC). The content of the sum of polyphenolic compounds is 50282.12 µg/g, and the sum of flavonoids is 25553.71 µg/g. Amongst the compounds identified are chlorogenic acid, caffeic acid, catechin, rutin, quercetin, myricetin and myricetin glycosides, naringin, naringenin, hesperidin, hesperetin, luteolin and luteolin glycosides, apigenin and apigenin glycosides [10, 15].

In the experiment that we conducted, rabbits weighing 2.0–2.5 kg were used. The animals were divided into three groups. Group 1 was a control group; group 2 were animals that had been intragastrically injected with DEWS at a dose of 30 mg/kg prior to modelling thrombophlebitis; group 3 similarly received Eskuvit 20 mg/kg as a reference drug – pills (JSC Halychpharm, Ukraine). The dose for animals was recalculated, taking into account body weight according to the Rybolovlev method [22].

The maintenance of vivarium conditions and experiments with animals were carried out in strong accordance with the main provisions of the Council of Europe

Convention on the Protection of Spine Animals Used in the experiment (plastic drinkers, balanced feed, free access to water) [23, 24].

Experimental thrombophlebitis was caused by injecting an intravenous solution of 2 % lugol at a dose of 0.1 ml into the marginal vein of the ear, having previously applied a ligature to the ear at a distance of 4 mm. Two hours later, rabbits formed a blood clot from 3.5–4.5 cm with an inflammatory surface of the soft tissues of the ear with an area of 700–1500 mm<sup>2</sup>. Transparent midi-meter paper was applied to the inflamed part of the rabbit's ear, a contour was applied, and the area of the hyperhymn was determined. The thrombus length was determined using the formula:

$$L = \frac{L_1 - L_2 * 100}{L_3},$$

where  $L_1$  – initial thrombus length;  $L_2$  – experiment day;  $L_3$  – number of days of experiment.

This model makes it possible to obtain a violation of blood flow due to inflammation of the venous wall, which is characteristic of most human thrombotic conditions [25].

The therapeutic and prophylactic effect of the studied drugs was observed for 10 days. The studied extract and the comparison drug were administered once a day intragastrically 3 days before the pathology simulation and throughout the experiment. For a more detailed assessment of the intensity of the pathological process in the vascular wall of the vein and its correction with the studied drugs, histological studies were performed in accordance with unified methods of light microscopy [26].

Statistical data processing was carried out using the Statistica for Windows 11.0 program based on variance analysis for repeated measurement data using the Mann-Whitney criteria at a probability level of  $p < 0.05$ .

#### 4. Research results

Against the background of the development of experimental thrombophlebitis in rabbits, the development of thrombosis of the ear vein and the inflammatory process of adjacent tissues were observed. The inflammatory process was accompanied by pronounced hyperemia and oedema. Prophylactic administration of DEWS for 6 days contributed to a decrease in the inflammatory process already on the 5th day of observation. The area of the injured area was 20 % smaller than in the control pathology group (CPG). Eskuvite showed a more pronounced protective effect compared to the CPG. The area of the injured ear area changed by 8 % compared to the CPG. On the 5th day of the experiment, the length of the thrombus in the study groups was less than in the CPG (Table 1).

By the end of the experiment, animals treated with DWS had a significant decrease in the length of the thrombus by 72 % ( $p > 0.05$ ), compared with the CPG; in the group of animals treated with Eskuvite, the decrease in the length of the thrombus was 62.5 %, respectively. In the control group of animals during the experiment, the area of hyperemia decreased slightly and, on the 10<sup>th</sup> day, was 32.4 % lower in comparison with the initial data. It should

be emphasized that DEWS showed a statistically more pronounced protective effect in comparison with the reference drug. According to the literature data, herbal medicines based on polyphenols and flavonoids exhibit protective vasoconstrictive properties, strengthen the endothelium of the venous wall, preventing the adhesion of cells with the endothelium, reducing inflammatory reactions, thereby reducing the radioprotective effect [19, 27].

The study data were confirmed morphologically. In intact rabbits, the outer and inner sides of the transverse profile of the studied ear area are bordered by the epidermis of the usual type. In the dermis of the skin proper, hair follicles and sebaceous glands are visible. Collagen fibers are dense, the cellular content is very moderate. The plate of fibrous cartilage, which represents the base of the ear, does not have a continuous character. Next to the cartilage plate, transverse profiles of the outer marginal vein of the ear, different arteries are visible. The lumen of the vein is narrow; in some rabbits, it is filled with blood. The wall is thin and undamaged. Intima is represented by endothelial cells (nuclei), which have an elongated shape, and the internal elastic membrane is poorly defined. The media is very thin; there is almost no muscle component in it, and collagen fibres are very thin and few in number. The outer shell of the vein is represented by an expressionless connective tissue. The tissues surrounding the vein have no signs of inflammation, oedema, or the usual architectonics (Fig. 1).

Table 1

Effect of Sakhalin willow shoots dry extract on ear inflammation area in rabbits against the background of experimental thrombophlebitis

Experiment groups	Thrombus square, mm <sup>2</sup>			
	1 <sup>st</sup> day	5 <sup>th</sup> day	8 <sup>th</sup> day	10 <sup>th</sup> day
Control pathology	505.1± ±11.2	412.5± ±12.3	390.3± ±10.8	341.5± ±9.66
DEWS 30 ml/kg	450.3± ±12.1	332.5± ±9.8*,**	291.5± ±8.18*,**	95.1± ±3.7*,**
Eskuvit 20 ml/kg	493.7± ±9.8	380.3± ±10.3*	315.5± ±7.71*	128.3± ±6.8*

Note: \*– statistical deviations valid in comparison with the CPG; \*\*– statistical deviations valid in comparison with the comparison drug; experimental data treatment (Mann-Whitney  $p > 0.05$ ).

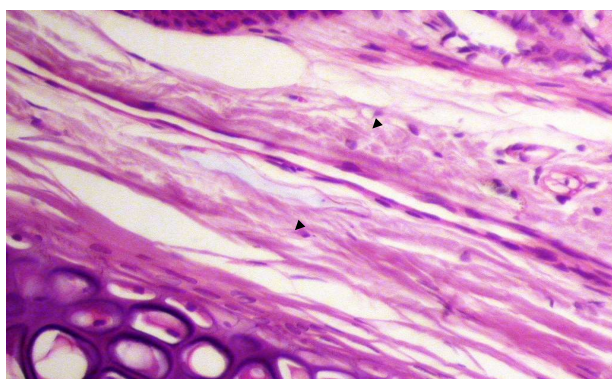


Fig. 1. Marginal vein of the ear of an intact rabbit. The condition of the external marginal vein and the surrounding ear tissues corresponds to the norm. Hematoxylin-eosin; ×200

*Model pathology.* Against the background of experimental thrombophlebitis, a change in the state of the marginal vein is observed in the studied areas of the ear. In the areas directly close to the injury zone, the lumen of the vein is clearly expanded, made by a fairly dense red thrombus. The vein wall is destroyed, and sometimes the adhesion of the thrombus with the wall or with the destructive remnants of the wall and with the surrounding tissues is visible. The blood flow in the vessel in this area is suspended. In the surrounding dermis, collagen fibres are in a state of degenerative oedema, and an inflammatory productive reaction is traced (Fig. 2).

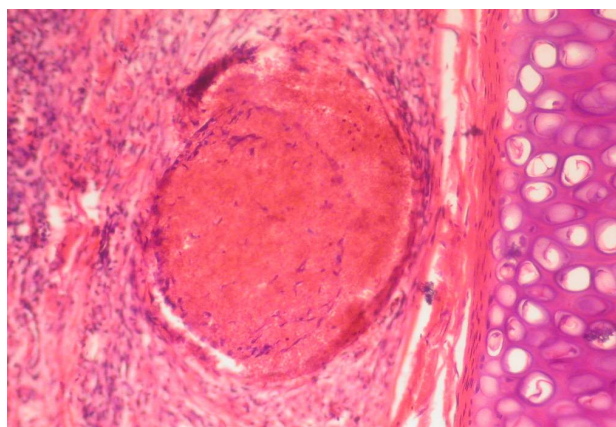


Fig. 2. The marginal vein in the rabbit's ear on the 10<sup>th</sup> day of the development of thrombophlebitis. A red blood clot clogs the lumen of the vessel; the vascular wall is destroyed in places (arrows), inexpressive softening of thrombotic masses, collagen fibres of the surrounding dermis are edematous, an inflammatory reaction in the skin itself. Hematoxylin-eosin; ×250

In the areas of the ear, more distant from the injury zone in the marginal vein, different expressiveness of thrombic mass lysis is visible; the stages of thrombus organization are its replacement with young connective tissue, vascular obliteration as well as fibrosis of perivascular tissue and signs of inflammation (Fig. 3).

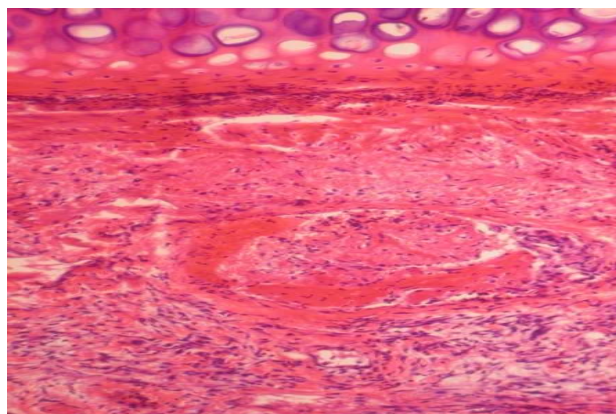


Fig. 3. The marginal vein of the rabbit's ear on the 10<sup>th</sup> day of the development of thrombophlebitis. Lysis of thrombotic masses, inflammation in perivascular tissue. Hematoxylin-eosin; ×200

In the rabbits that were injected with a dry extract of Sakhalin willow shoots against the background of thrombophlebitis, no clots were detected in the marginal vein of the ear throughout all the studied areas. The presence of wall-mounted thrombi was observed in the areas of the ear close to the ligature site in the enlarged lumen of the vessels; the material of the thrombotic masses was noticeably softened. The vein wall in some rabbits is focally destroyed. There are no degenerative changes in the collagen matrix of the skin itself, and the inflammatory reaction perivasally is significantly less (Fig. 4).

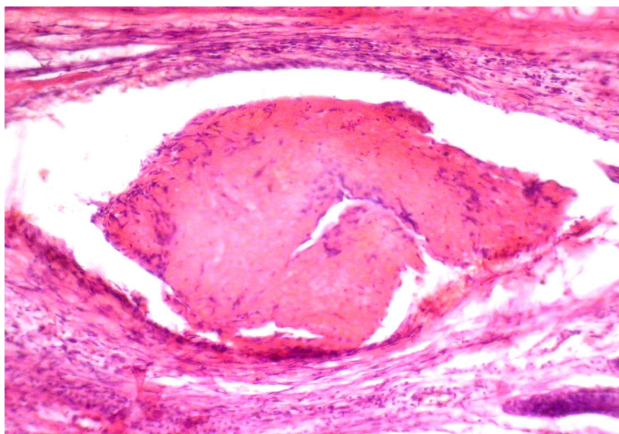


Fig. 4. The marginal vein of the rabbit's ear on the 10<sup>th</sup> day of the development of thrombophlebitis and parallel injection of dry extract of Sakhalin willow shoots. A wall thrombus in the enlarged lumen of the vein, focal damage to the vascular wall, the inflammatory reaction perivasally is clearly reduced. Hematoxylin-eosin; ×200

In the areas of the ear more distant from the place of ligature application along the vein, a thrombus in the lumen is either small near-wall or absent. Irritated erythrocyte masses are often visible, blood flow in the vessels is free, and fibrosis of the vascular wall is not visible. The condition of the marginal vein is close to intact. Violation of microcirculation and signs of inflammation in the tissues of the ear proper has not been determined.

Against the background of the introduction of the comparison drug Eskucvit in the preventive and therapeutic regime against the background of the development of thrombophlebitis, the marginal vein in the area close to the injury site is quite expressively expanded, but its wall is not destroyed. A blood clot can be seen in the lumen of the vessel, which clogs the lumen. The thrombus material is unevenly softened, and the signs of inflammation are not pronounced (Fig. 5).

A little further along the vein, a blood clot in the lumen persisted. There are signs of organization in it (Fig. 6), and also, in parallel with it, the processes of sewerage are observed – manifestations in the connective tissue which replaced the thrombus material of newly formed capillaries thanks to which blood flow is restored in this part of the vein. The vascular wall is slightly thickened, and there is no perivascular fibrosis.

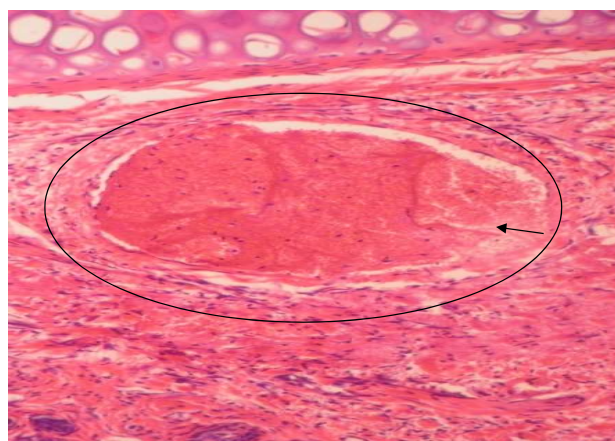


Fig. 5. The marginal vein of the ear of the rabbit on the 10<sup>th</sup> day of the development of thrombophlebitis and parallel injection of Eskucvit. The thrombus clogs the lumen of the vessel; the thrombotic masses are unevenly softened, and the vascular wall is not damaged. Hematoxylin-eosin. ×250

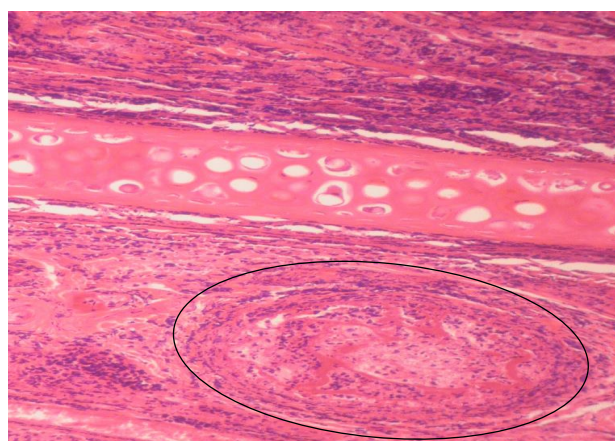


Fig. 6. The marginal vein of the rabbit's ear on the 10<sup>th</sup> day of the development of thrombophlebitis and parallel administration of Eskucvit. In the lumen of the marginal vein (oval), a thrombus with signs of organization is visible; the vascular wall is soldered to the surrounding tissue, causing an inflammatory reaction in the skin itself. Hematoxylin-eosin; ×200

## 5. Discussion

Based on the obtained microscopic data, it can be concluded that a temporary stop of blood flow in a limited area of the marginal vein of the ear with the simultaneous introduction of lugol solution into its space leads to pathological changes in both the vessel itself and the surrounding tissues. On the 10<sup>th</sup> day of pathology development, a microscopic picture of marginal vein thrombosis with lumen obstruction, destruction of the vascular wall, and degenerative and inflammatory changes in the skin tissues surrounding the vessel was observed on micropreparations. In the course of the vein, different stages of thrombus organization were observed – from the disintegration of erythrocytes and leukocytes, the appearance of connective tissue cells, to complete overgrowth of the lumen with connective tissue, stopping blood flow in this area, as well as vascular sclerosis wall of different expressiveness, perivascular fibrosis.

The use of dry extract of Sakhalin willow shoots, simultaneously with the development of pathology, prevented the formation of blood clots that clogged the lumen of blood vessels and contributed to the softening of the material of small blood clots and thrombolysis. As a result of all this, the material of the thrombus disintegration was 'washed away' by the blood flow and, in contrast to the model pathology, the blood flow was restored in the studied area of the ear. Dry extract of Sakhalin willow shoots prevented the destruction of the vascular wall and reduced or eliminated degenerative changes and inflammatory reactions of surrounding tissues, which is due to its phytochemistry (flavonoids and salicylic acids) and is consistent with literature data [16, 17, 28, 29].

It has been found that bioflavonoids exhibit p-vitamin activity, improve microcirculation and trophic tissues, reduce congestion in the veins, and have thrombolytic, phlebotropic and anti-inflammatory effects [28, 29].

The comparison drug Eskuvit on this experimental pathology model had a less significant effect on the process of thrombosis, softening of the thrombus material and thrombolysis, but contributed to the 'acceleration' of its sewerage, which also contributed to the renewal of blood flow in the vessel. Under the influence of Eskuvit, inflammatory manifestations in the ear tissues decreased.

According to the positive effect on the histological manifestations of experimental thrombophlebitis, the dry extract of the shoots of the Sakhalin willow was superior to the comparison drug Eskuvit.

**Research limitations.** Pharmacological studies are limited to the constituent of the phytoextract.

**Further research prospects.** Consequently, it is planned to study the effect of pharmacodynamic properties of phytoextract on anticoagulant properties and platelet aggregation inside the vascular bed. This phytoextract is planned to be investigated as a means for the prevention and treatment of varicose veins of the lower extremities.

## 6. Conclusions.

1. DEWS administered in a therapeutic and prophylactic mode at a dose of 30 mg/kg exhibits anti-inflammatory, thrombolytic and venoprotective effects in conditions of experimental thrombophlebitis of peripheral veins in rabbits.

2. Comparative analysis showed that, according to the activity of the effect on thrombophlebitis indicators, dry extract of Sakhalin willow shoots had a more pronounced thrombolytic activity on the process of thrombosis and thrombolysis compared with Eskuvite pills.

3. The results of the conducted studies allow us to recommend DEWS as a venoprotective agent with thrombolytic activity for further study.

## Conflict of interest

The authors declare that they have no conflict of interest in relation to this research, whether financial, personal, authorship or otherwise, that could affect the research and its results presented in this article.

## Funding

The study was performed without financial support.

## Data availability

Data will be made available on reasonable request.

## Acknowledgement

We express gratitude to Senior Researcher Y. B. Larianovska for her consultative assistance. Raw material samples of *Salix sachalinensis* F. Schmidt were obtained with the assistance of Liudmyla Iakiva Lukashchuk, Deputy Director for Research of the Institute of Agriculture of Western Polesia of the National Academy of Agrarian Sciences of Ukraine. We are sincerely grateful for the assistance and the opportunity to acquire raw materials.

## References

1. ASH Releases New Clinical Practice Guidelines for Venous Thromboembolism. Evidence-Based Guidelines to Drive Improved Care for Patients with Blood Clots (2018). Washington.
2. Sandor, T. (2017). Superficial venous thrombosis. A state of art. *Orvosi Hetilap*, 158 (4), 129–138.
3. Raffetto, J. D., Eberhardt, R. T. (2015). Benefit of anticoagulation for the treatment of lower extremity superficial venous thrombosis. *Journal of Vascular Surgery: Venous and Lymphatic Disorders*, 3 (2), 236–241. doi: <https://doi.org/10.1016/j.jvsv.2014.11.005>
4. Dmitrieva, I., Krivoshechekov, E. (2018). Flebological help patients with complicated forms of chronic venous insufficiency. 24 Conference of the European Wound Management Association EWMA. Madrid, 360.
5. Galanaud, J. -P., Sevestre, M. -A., Pernod, G., Kahn, S. R., Genty, C., Terrisse, H. et al. (2017). Long-term risk of venous thromboembolism recurrence after isolated superficial vein thrombosis. *Journal of Thrombosis and Haemostasis*, 15 (6), 1123–1131. doi: <https://doi.org/10.1111/jth.13679>
6. Shevela, A. I., Usov, S. A., Markina, V. A. (2019). Obesity and Chronic Venous Insufficiency: from Risk Factors to Pathogenesis. *Flebologija*, 13 (3), 220–226. doi: <https://doi.org/10.17116/flebo201913031220>
7. Pannier, F., Rabe, E. (2015). Progression in venous pathology. *Phlebology: The Journal of Venous Disease*, 30 (1), 95–97. doi: <https://doi.org/10.1177/0268355514568847>
8. Zhao, J., Maitituersun, A., Li, C., Li, Q., Xu, F., Liu, T. (2018). Evaluation on Analgesic and Anti-Inflammatory Activities of Total Flavonoids from *Juniperus sabina*. *Evidence-Based Complementary and Alternative Medicine*, 2018, 1–9. doi: <https://doi.org/10.1155/2018/7965306>
9. Le, N., Herz, C., Gomes, J., Förster, N., Antoniadou, K., Mittermeier-Kleßinger, V. et al. (2021). Comparative Anti-Inflammatory Effects of *Salix* Cortex Extracts and Acetylsalicylic Acid in SARS-CoV-2 Peptide and LPS-Activated Human In Vitro Systems. *International Journal of Molecular Sciences*, 22 (13), 6766. doi: <https://doi.org/10.3390/ijms22136766>
10. Borodina, N. V. (2021). Pharmacognostic study of willow plants and creation of medicines based on them. *Kharkiv*, 575.

11. Sinchenka, V. M. (Ed.) (2015). Enerhetychna verba: tekhnolohiia vyroshchuvannia ta vykorystannia. Vinnytsia: TOV «Niland-LTD», 340.
12. Vorobei, V., Melekh, Ya., Hudz, N. (2018). Vykorystannia biomasy enerhetychnykh kultur u pivnichnykh oblastiakh Ukrainy: Volynska, Rivnenska, Zhytomyrska, Kyivska ta Chernihivska oblasti. Lviv, 59.
13. Energeticheskaia verba: kak vyrastit i skolko na etom mozhno zarobotat znaiut na Rovenshchine (2016). Available at: <https://ecotechnica.com.ua/.../708-energeticheskaya-verba-kak...>
14. Borodina, N., Raal, A., Kovalyov, V., Koshovyi, O., Ilina, T. (2020). Macro- and Microelements in the Branches of some Salix Genus Species in the Flora of Ukraine. International Journal of Pharmaceutical Research & Allied Sciences, 9 (3), 71–80.
15. Borodina, N., Kovalyov, V., Koshovyi, O. (2021). Reserch of raw material and extracts of salixsachalinensis. F. Schmidt. Norwegian Journal of development of the International Science, 1 (55), 42–47.
16. Borodina, N. V., Kovalov, V. M., Stremoukhov, O.O. (2015). Pat. No. 98912 UA. Sposib oderzhannia kompleksnoho sukho ho ekstraktu z roslynnoi syrovyny. No u201413010; declared: 04.12.2014; published: 12.05.2015, Bul. No. 9.
17. Borodina, N. V., Kovalev, V. N. (2015). Comparative analysis of phenolic compounds shoots Salix caprea L., Salix purpurea L., Salix viminalis L. Flora of Ukraine. Fenolnye soedineniia: fundamentalnye i prikladnye aspekty. Moscow, 27–33.
18. Maloshtan, L. M., Artemova, K. O., Shatalova, O. M. (2021). Study of analgesic and anti-inflammatory activity of dry extract from sakhalin willow shoots. Farmatsevychnyi Zhurnal, 4, 103–110. doi: <https://doi.org/10.32352/0367-3057.4.21.09>
19. Maloshtan, L. M., Kalenichenko, G. S., Dorovskyy, O. V. (2015). The study of the action of the thick extract from the leaves of Corylus avellana on the vascular tissue permeability. Clinical pharmacy, 19 (4), 26–29. doi: <https://doi.org/10.24959/cphj.15.1362>
20. Gloviczki, P., Comerota, A. J., Dalsing, M. C., Eklof, B. G., Gillespie, D. L., Gloviczki, M. L. et al. (2011). The care of patients with varicose veins and associated chronic venous diseases: Clinical practice guidelines of the Society for Vascular Surgery and the American Venous Forum. Journal of Vascular Surgery, 53 (5), 2S–48S. doi: <https://doi.org/10.1016/j.jvs.2011.01.079>
21. Guyatt, G. H., Akl, E. A., Crowther, M., Gutterman, D. D., Schünemann, H. J. (2012). Executive summary: Antithrombotic Therapy and Prevention of Thrombosis, 9th ed: American College of Chest Physicians Evidence-Based Clinical Practice Guidelines. Chest, 141 (2), 7S–47S. doi: <https://doi.org/10.1378/chest.1412s3>
22. Rybolovlev, Iu. R., Rybolovlev, R. S. (1979). Dozirovanie veshchestv dlia mlekopitaiushchikh po konstantam biologicheskoi aktivnosti. Doklady AN SSSR, 247 (6), 1513–1516.
23. Evropeiskaia konventciia o zashchite pozvonochnykh zhivotnykh, ispolzuemykh dlia eksperimentov ili v inykh nauchnykh tceliakh (1986). Available at: <https://rm.coe.int/168007a6a8>
24. Ekspertnyi vysnovok komisii z bioetyky (2019). Natsionalnyi farmatsevychnyi universytet, m. Kharkiv, protokol No. 6.
25. Maloshtan, L. M., Dolzhykova, O. V., Batura, I. O. (2002). Sposib modeliuвання tromboflebitiv pereferiinykh sudyn: informatsiinyi lyst vid 20.11.2002 r. No. 251. Kyiv: Ukrmedpatentprom, 3.
26. Khabriev, R. U. (2005). Rukovodstvo po eksperimentalnomu (doklinicheskomu) izucheniiu novykh farmakologicheskikh veshchestv. Moscow: OAO «Izdatelstvo «Meditsina», 832.
27. Lobastov, K. V., Dementieva, G. I., Laberko, L. A. (2019). Current Insights on the Etiology and Pathogenesis of Venous Thrombosis: Virchow's Triad Revision. Flebologija, 13 (3), 227–235. doi: <https://doi.org/10.17116/flebo201913031227>
28. Kurkin, V., Zaitseva, E., Morozova, T., Pravdivtseva, O., Avdeeva, E., Kurkina, A. et al. (2018). The study of the flavonoids and antidepressant activity of the leaves and liquid ex-tract of crataegus submollis. Chemistry of Plant Raw Material, 4, 105–112. doi: <https://doi.org/10.14258/jcpr.2018043883>
29. Kurkin, V. A., Zaitseva, E. N., Morozova, T. V., Pravdivtseva, O. E., Dubishchev, A. V., Kurkina, A. V. et al. (2019). Comparative Investigation of the Diuretic and Anti-Depressant Activity of Liquid Extracts of Crataegus Sanguinea. Journal of Pharmaceutical Sciences and Research, 11 (1), 30–32.

*Received date 04.04.2023*

*Accepted date 23.08.2023*

*Published date 31.08.2023*

**Liudmyla Maloshtan**, Doctor of Biological Sciences, Professor, Department of General Pharmacy, Educational and Scientific Medical Institute, National Technical University “Kharkiv Polytechnic Institute”, Kyrpychova str., 2, Kharkiv, Ukraine, 61002

**Kateryna Artemova**, Department of Technologies of Pharmaceutical preparations, National University of Pharmacy, Pushkinska str, 53, Kharkiv, Ukraine, 61002

**Natalia Borodina**, Doctor of Pharmaceutical Sciences, Associate Professor, Department of Pharmacognosy, National University of Pharmacy, Pushkinska str, 53, Kharkiv, Ukraine, 61002

**Oleksandr Kukhtenko**, Doctor of Pharmaceutical Sciences, Professor, Head of Department, Department of Technologies of Pharmaceutical Preparations, National University of Pharmacy, Pushkinska str, 53, Kharkiv, Ukraine, 61002

*\*Corresponding author: Natalia Borodina, e-mail: natalijaborodina@gmail.com*