

Надійшла 01.12.2021

Акцептована 02.03.2022

УДК 616.66-089

DOI 10.26641/2307-5279.26.1.2022.260491

Comparison of implant methods for penis enlargement

I.E. Aguilar¹, orcid: 0000-0002-6445-6512, e-mail: aguilar2467@gmail.com

O.V. Knigavko², orcid: 0000-0002-8870-3450, e-mail: aknig79@gmail.com

D.M. Choi³, orcid: 0000-0001-5194-2514, e-mail: mchoi@dersmithson.com

K. Sangjin³, orcid: 0000-0002-0292-6865, e-mail: sjkim@dersmithson.com

¹ *Mexico Phalloplasty center, Mexico, Mexico*

² *Kharkiv National Medical University, Kharkiv, Ukraine*

³ *Dersmithson sp, Jagelonska University (JCI), Krakow, Poland*

Keywords:

penis enlargement, length and circumference of penis, silicone implant, porous polylactic acid matrix, autologous stem cells, vascular endothelial growth factor

For citation:

ДСТУ 8302 2015:

Aguilar I.E., Knigavko O.V., Choi D.M., Sangjin K. Comparison of implant methods for penis enlargement. *Урологія*. 2022. Т. 26, № 1. С. 41–50. DOI: 10.26641/2307-5279.26.1.2022.260491.

APA:

Aguilar, I.E., Knigavko, O.V., Choi, D.M., & Sangjin, K. (2022). Comparison of implant methods for penis enlargement. *Urologiya*, 26(1), 41–50. DOI: 10.26641/2307-5279.26.1.2022.260491.

SUMMARY

Male dissatisfaction with the penis size is the most common manifestation of penile dysmorphism. Despite the diversity of penis enlargement methods a single safe technique that fully satisfies patients has not yet been developed.

The aim of this work is to compare the results of a combined operation on installation of a silicone implant or a collagen matrix impregnated with autologous stem cells with simultaneous ligamentotomy to increase the length and circumference of the penis.

In 2017–2022 there were performed penis enlargement surgeries in 2 centers. In Public Non-Profit Organization Of The Kharkiv District Council «Kharkiv Regional Clinical Center Of Urology And Nephrology Named After V.I.Shapoval (Kharkiv, Ukraine) 38 patients from Ukraine and Poland were operated by Professor Knigavko O.V. with implantation of a porous Max Pol matrix (manufactured by Dersmithson, M.D. Choi), and in the “Mexico phalloplastic center” (Mexico city, Mexico) by Dr. Aguilar I.E. implantation of non-absorbable silicone implants in 36 patients was performed. The results of penis enlargement were evaluated in the early (2 months) and long-term (6 months) terms.

While implanting a silicone implant the majority of the patients – 31 (86.1%) are satisfied with the result, 27 (75%) patients mention an improvement in sexual life, 31 (86.1%) also mention an increase in their own self-sufficiency. At the same time, some patients mentioned the following complications: 2 (5.6%) patients mentioned displacement of the silicone matrix, 1 (2.8%) patient mentioned prolapse of the matrix, 1 (2.8%) patient mentioned a decrease in erection (which did not improve after removal of the matrix), in 1 (2.8%) case the silicone implant had to be removed due to the fact that the patient did not like the appearance.

While using a collagen-like matrix made of polymerized polylactic acid impregnated with own stem cells in 38 patients, we haven't seen any complications that caused the removal of the matrix.

However, 5 (13.2%) patients required additional poly-lactic acid gel injections between 6 and 36 (97.4%) months to optimize the shape or volume of the penis. 34 (89.5%) patients mentioned an improvement in the sexual function and sexual sensations of their partner, harmonization of relationships in a couple, and 36 (97.4%) men – an increase in a sense of self-sufficiency.

Thus, modern implants can improve the size and appearance of the penis, improve the quality of sexual life and the feeling of self-sufficiency in operated men. The use of silicone implants is simpler, almost does not require specific rehabilitation after surgery, however, in a small part of patients prolapse of the prosthesis and dissatisfaction with the final result are present. Most of operated patients were satisfied with results of silicone implant. The use of a polymer matrix impregnated with own stem cells requires a special laboratory, more time for preoperative and postoperative rehabilitation, however, it is more physiological and can be considered as a standard for safe penis enlargement.

INTRODUCTION

Вступ

Nowadays many men want to increase both the length and thickness of the penis due to dissatisfaction with existing sizes. A small penis, according to the patients, is one of the main reasons of their self-doubt, low self-esteem and sexual deficiency [11]. This desire is manifested especially often among those people who want to achieve a certain social status and a leading position in society. Thus, penis enlargement gets rid men of psychological problems and imposed complexes that prevent them from showing their full potential [8]. The size of the penis affects not only self-confidence, but also the general health of men, including the well-coordinated work of the endocrine and reproductive systems [1].

Today there is no established average erected penis size. It depends on such factors as heredity, hormonal levels, as well as nationality and race. For example, in Ukraine the average size of an erect penis is 14.2 cm, ranging from 12 to 18 cm, with a size of less than 12 cm being small and less than 10 cm being very small (micropenis). But at the same time, the average size of the penis among Asian men is 9 cm, which for Ukrainians is considered as a deviation from the norm [14].

Penis enlargement can be done not only because of the personal desire of a man (as in most cases), but also for medical reasons including micropenis, hidden penis, Peyronie's disease, hypospadias, epispadias, and penile insufficiency. The main reason of micropenis is the insensitivity of receptors of the cavernous bodies to testosterone. Basically, this condition is accompanied by other anomalies of the reproductive system [3]. The small size can also

be due to the hidden penis caused by insufficiency of the skin sheath. But at the same time it is important not to mistake the true hidden penis for a false one where the cavernous bodies have a normal size, but they are not visible under the excess subcutaneous fat of the lower abdomen.

Does the penis size affect satisfaction with the quality of a sex life in a couple? It is known that the achievement of a vaginal orgasm by a woman is affected not so much by the length as by the circumference of the penis. That is due to the fact that the diameter of the penis is much more important while stimulating the most sensitive areas of the female genital organs, including the labia minora and the clitoris.

Modern penis enlargement methods.

Medical methods. It consists of the use of testosterone and gonadotropic hormones during enhanced puberty period, which are prescribed to boys aged 13–16 years with reduced testosterone levels. At the same time, substitution therapy and stimulating hormonal therapy does not have any effect on the size of the penis in adulthood.

Conservative methods.

1. Manual methods.

First of all, these include jelqing (translated from Arabic – “milking”) – a complex of self-massage of the penis, aimed at stretching of the tissues. As a result of its implementation, blood circulation increases, the skin of the penis becomes more elastic and flexible, and erectile function also improves. The mechanism of this technique is that blood pressure is created in the cavernous bodies, which contributes to the stretching of the cavernous chambers. A slight tissue trauma provides the creation of new cells and an increase in the size of the penis respectively. If this practice is performed daily for 3 months straight,

penis enlargement by a maximum of 1–2 cm is possible. Jelqing can be performed in a dry and wet (using cream or lubricant) method.

Contraindications include skin injuries, Peyronie's disease, sexually transmitted diseases, genital warts and tumors of the pelvic organs.

2. Hardware-based methods.

These include the use of extenders of various types and models. Extender is a special medical orthopedic device for penis enlargement and correction of its shape. The mechanism of its action is the long-term mechanical stretching of tissues. This provides the release of growth hormone and cell division, which leads to an enlargement of the penis. In addition, under the influence of the extender, the activity of the metalloproteinase enzyme is enhanced, resulting in tissue remodeling, scar resorption and collagen breakdown [5].

There are a number of extenders depending on how the head is attached to it and on the tension mechanism:

- harness;
- strap;
- vacuum cap;
- vacuum adhesive.

The main recommendation for using the extender is to wear it daily from 4 to 6 hours for 6–8 months. Therefore, this method is suitable for those patients who are willing to spend time to achieve the desired result. This allows you to increase the penis by 1–2 cm in length and 1–1.5 cm in diameter while using a vacuum pump. When wearing the extender, there may be sensations of tingling and stretching of tissues in the groin area.

Contraindications include varicocele, varicose veins of the penis, prostate adenoma, prostatitis, diabetes mellitus, vascular disease and infections of the genitourinary system. Wrong wearing of the extender can lead to stretching of the tunica albuginea of the cavernous bodies, insufficiency of the valvular apparatus and the formation of veno-occlusive erectile dysfunction [4].

A variation of the extender is a stretcher, the main difference of which is the absence of rigid rods. It is designed on the basis of an elastic strap that is attached to the head of the penis and is fixed on certain parts of the body, depending on the type of stretcher. It can be easily hidden under loose-fitting clothing, allowing you to use the device outside the home as well as during sleep. This, in turn, maintains tissue tension when it is impossible to wear the extender for a long time. With the help of a stretcher, it is possible to increase the penis by 1–1.5 cm [6].

Types of stretcher depending on the direction of thrust:

- shins (legs);
- waist;
- with pull up;
- vacuum.

Contraindications include various injuries of the penis, skin diseases and anomalies in the development of the penis.

Another hardware method of penis enlargement is the use of a hanger. A hanger is a special device for hanging a load to the penis. Its mechanism of action is to stretch the tissues in a downward direction, which stretches mainly the upper and lateral ligaments that attach the penis to the pubis. But the main disadvantage is its mandatory wearing in a stationary state, standing, sitting or lying down. The minimum weight of the suspension that is used at the initial stage is 200–250 g and reaches maximum values at the final stages of penis enlargement at 1250 g.

There is a recommended scheme for alternating the above mentioned hardware methods for penis enlargement, which consists in wearing an extender in the morning, a stretcher in the afternoon and a hanger in the evening for two hours, respectively, which allows for a long-term stretching effect on the tissues of the penis for at least 6 hours a day. In this case, the lengthening of the penis occurs on average by 1.5–2.5 cm and is partially preserved for the rest of your life by 1–1.5 cm.

3. The use of vacuum pumps.

A vacuum pump is a special flask into which the penis is placed, forcing a large volume of blood by creating negative pressure in a vacuum. But this method has a number of disadvantages. Despite the fact that the penis becomes much larger externally while using a vacuum pump, there can be irreversible changes in the structure of the penis including lymphatic edema of the penis, edema of the foreskin and rupture of blood vessels. These damages begin to develop after 15–20 minutes of wearing the pump, and the indicated time is clearly not enough to actively stimulate cell division. Due to the consequences of using the pump, this method is completely ineffective for penis enlargement as a standalone method, but can be used as an addition to penile traction programs [13].

In order to avoid injury of the penis, more often they resort to the use of a hydropump – a device represented by a flask and a corrugated spring which creates an internal tensile effect. On the back of the flask there is a valve through which the liquid flows out. The suction action occurs under the influence of warm water, which is pumped out of the flask. Thus, the hydropump limits the direct contact of the skin of the penis with the area of rarefied air, thereby reducing the risk of bruising as in the case

of a vacuum pump. In addition, the procedure takes only 15–20 minutes, and the effect is noticeable after the first application. With constant use it is possible to achieve penis enlargement up to 10–15%.

Surgical techniques. Ligamentotomy is the most effective way to increase the size of the penis. This method consists of cutting the suspensory ligament and pulling the inside of the penis outward. As it is known, the penis consists of an external and an internal part. The area that is located in the subcutaneous fat and is connected to the pelvic bones with the help of a ligamentous apparatus is called internal. After the operation, the penis is lengthened and the surgical area is replaced with new connective tissue [2].

The main indication is the desire of a man, but ligamentotomy is also performed due to Peyronie's disease, congenital micropenis, cavernous fibrosis, epispadias and hypospadias.

The elongation of the penis after this operation reaches 2.5–4 cm. But when using an extender or stretcher in the postoperative period, there is an additional stretching and prevention of retraction of the hidden part of the penis, which gives a total elongation of 5–6 cm. The maximum total result is 8–9 cm when performing an integrated approach, which includes ligamentotomy, traction with an extender, the use of a vacuum pump or hydropump, as well as injections of PRP and autologous stem cells. In addition, with proper postoperative rehabilitation the result will remain forever.

Methods for thickening the penis. This procedure is common among patients who want to satisfy their partner, as thickness is more important for a qualitative sex life. A survey was conducted among women with a visual demonstration of a 3D model of the penis, as a result of which 4 cm is considered the most optimal diameter of the male genital organ [7]. If there is an inconsistency in indicated "norm" of the size of the penis in the circumference and dissatisfaction with the sexual life of both men and women, we offer several options for thickening the penis, among which the most relevant are lipofilling (subcutaneous injection of one's own fat), the filler injection (hyaluronic acid gel or polylactic acid), implantation of prolene meshes and thickening with a collagen matrix or silicone implant.

Lipofilling is the filling of the penis with excess fat taken from the abdomen, thighs or buttocks through liposuction. Usually, the amount of fat taken is no more than 30–50 ml. It is necessary to purify the fat from the blood fraction.

The resulting lipocytes (fat cells) are injected with a microneedle along the entire shaft of the penis. The duration of the operation is approximately

1 hour; it is performed under general anesthesia, which makes the procedure absolutely painless. The thickening of the penis with this method is up to 3–4 cm in circumference. At the same time, the effect remains for 6–8 months, during this time the volume of filling is decreasing by half, but if necessary, a second procedure is possible. There were cases with formation of oleogranulomas or scarification (scar formation due to the growth of connective tissue) of the penis is possible [9].

The main restriction after the operation is abstinence from sexual intercourse for 3–4 months.

The advantage of lipofilling is the almost complete survival rate of the transplanted tissue due to the use of its own cells. But it is worth noting that over time blood vessels can grow into fatty tissue, so the fat will partially disappear from the penis, and in some areas the fatty tissue will remain in its original place, while in others it will disappear due to the immune response of the body. Therefore, after a while, penis enlargement may look uneven and unaesthetic due to uneven thickness.

As an alternative, the use of hyaluronic or polylactic acid fillers is proposed [12]. Filler injections are performed around the entire circumference of the penis, except for the urethra zone. The maximum allowable volume of injected filler is 50–60 ml. After the procedure a man can return to his previous lifestyle by limiting physical activity, taking a hot bath and visiting a sauna or bath for 2 days. It is also necessary to refrain from sexual intercourse for 2 weeks.

The use of fillers allows to achieve a thickening of the penis up to 1.5–2 cm in diameter. But the effect from the hyaluronic acid injection lasts up to 1–1.5 years on average, and polylactic acid – up to 2–2.5 years. This is due to the fact that the injected substance undergoes gradual resorption by body tissues. Therefore, to maintain the desired result, repeated injections of fillers are required at least once every 1–1.5 years, what is a disadvantage of this method.

With hyaluronic acid injections, the glans penis can also be enlarged to recreate volume and shape, as well as to reduce the sensitivity of the glans in order to lengthen sexual intercourse.

The duration of the procedure is no more than 10 minutes and is also performed under local anesthesia. After the effect of an anesthetic, 4–8 ml of hyaluronic acid gel is injected under the mucosa around the entire circumference of the glans penis. After the procedure, within a few weeks, it is possible to increase the volume of the glans penis by 10–15% due to the fact that hyaluronic acid has the ability to attract water. In addition to increasing the size, the head becomes elastic, its skin smooth, without

folds and visible wrinkles. The result remains for 10–16 months.

It is recommended to limit the intake of warm showers, visits to saunas, baths and physical activity in the next 2–3 weeks. It is also necessary to refrain from sexual intercourse for at least 2 weeks.

One of the most effective methods of thickening the penis is the use of a special collagen matrix [10]. This method is the installation of a cylinder with a collagen or collagen-like (from polymeric polylactic acid) matrix in the shaft of the penis which stimulates the formation of new connective tissue and activates cell division of the cavernous bodies in the penis. Pre-impregnation with its own cells significantly improves the processes of engraftment of the matrix and activates the growth of fibroblasts. The operation, as a rule, is performed from the suprapubic approach with simultaneous ligamentotomy and penilization of the skin of the suprapubic region. After the operation, the patient stays in the hospital from 1 to 3 days.

After 18–30 months, the matrix completely dissolves and is replaced by its own tissue, due to which the penis thickens by 0.8–1 cm in diameter, that is, 4–4.5 cm in circumference. This excludes the possibility of sexual intercourse for 1.5–2 months after the surgery.

The use of gel (silicone) implants is an experimental and quite effective method of penis thickening today. In this case, a thickening of up to 1.5 cm in diameter is achieved and the result is noticeable immediately after the procedure. The duration of the operation is approximately 60 minutes. Sexual life can be resumed within a month after the procedure.

Due to the variety of methods, we decided to analyze the short- and long-term results of the most effective implant techniques: the installation of silicone non-absorbable implants and a collagen-like polylactic acid matrix impregnated with autologous stem cells.

MATERIALS AND METHODS

Матеріали і методи дослідження

From 2017 to 2022 in 2 specialized centers “Kharkiv Regional Clinical Center Of Urology And Nephrology” Named After V.I.Shapoval (Kharkiv, Ukraine) and “Mexico phalloplastic center” (Mexico, Mexico)) 74 men with penile dysmorphophobia were examined and operated. The reason for surgery in all patients was dissatisfaction with the size of the penis – penile dysmorphophobia.

The average age of patients ranged from 34 to 45 years (average 39.5 ± 5.4).

In order to objectify and quantify the symptoms of erectile and orgasmic dysfunction, as well as disorders of sexual and general satisfaction of patients, the IIEF questionnaire was used. If the total score did not exceed 10, this indicated severe erectile dysfunction, from 11 to 21 – moderate ED, and from 22 to 25 – mild ED, 26–30 – no ED.

To assess male depression associated with dissatisfaction with penis size, the Hamilton Scale (HDRS) (17-item version) was used, one of the most widely used tools for clinical assessment of depression, providing a simple way to assess the severity of depression and reflecting the dynamics of changes the patient’s condition. The assessment of the total score indicated: 0–7 – the norm; 8–13 – mild depressive disorder; 14–18 – depressive disorder of moderate severity; 19–22 – severe depressive disorder; more than 23 – depressive disorder of extremely severe severity.

38 patients of the 1st group from Ukraine and Poland (Public Non-Profit Organization Of The Kharkiv District Council “Kharkiv Regional Clinical Center Of Urology And Nephrology Named After V.I.Shapoval” (Kharkiv, Ukraine) were implanted a collagen-like matrix of polylactic acid Max Pol (manufactured by Dersmithson, M.D. Choi) by Professor Knigavko A.V (fig. 1). 36 patients of the 2nd group “Mexico phalloplastic center” (Mexico, Mexico) were operated non-absorbable silicone implants by Dr. Aguilar I.E (fig. 2).

The implants were installed from the peno-pubic incision (above the penis) from the transverse or rhomboid incision simultaneously with ligamentotomy. A small silicone implant was placed between the penis and the pubic symphysis to prevent refixation of the penis to the pubic bones.

Porous matrix of polylactic acid was impregnated with 4 million autologous stem cells before implantation (isolated from peripheral blood by magnetic separation and multiplied in a bioreactor) and fixed to the membranes at the base of the penis.

The main silicone implant was fixed to the Bach fascia of the penis under the head to prevent its displacement.

The results of surgical penis enlargement were evaluated in the early (2 months) and long-term (6 months) terms.

To evaluate the effectiveness of treatment methods, the obtained digital data were processed by methods of mathematical statistics. Differences between groups were considered statistically significant at $p < 0.05$. Data are presented as $M \pm SD$ (M is the arithmetic mean, SD is the standard deviation). Mathematical processing of research results was carried out using

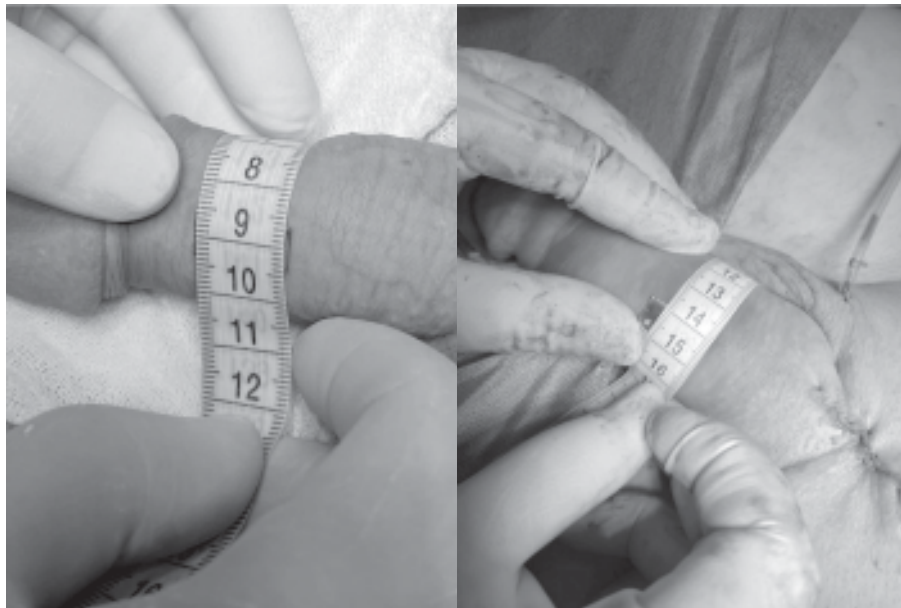

FIGURE 1. Implantation of polymerse PLLA scaffolf with ASC

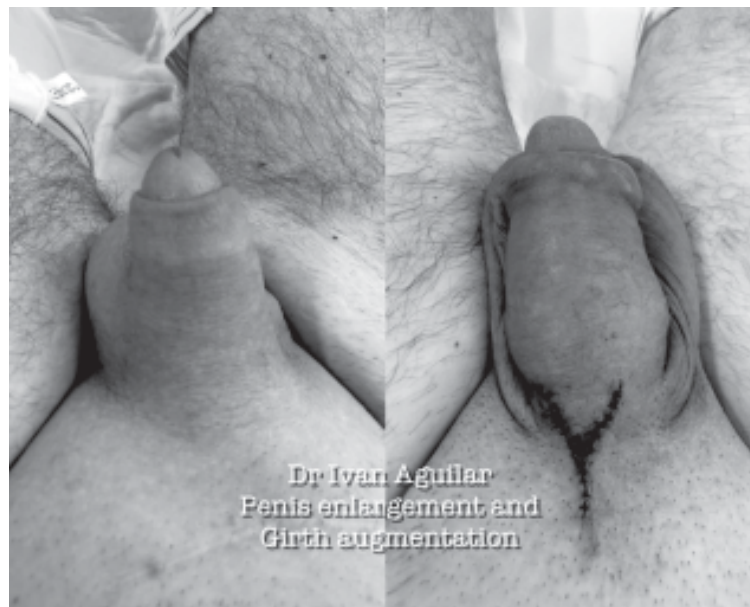

FIGURE 2. Implantation of silicone implant

the application package of licensed statistical programs Statistica for Windows 7.0 and Excel spreadsheet editor Microsoft (USA).

RESULTS AND DISCUSSION

Результати та їх обговорення

In all patients, there is a decrease in the sense of self-sufficiency, the aggravation of relationships with a partner. Despite normal libido, 63 (85.1%) identified men had psychogenic erectile dysfunction and a lack of sexual behavior (table 1), 58 (78.4%) were diagnosed with moderate and heavy depressive disorders, severe emotional distress and neurasthenia

(table 2). The absence of significant differences in the studied indicators shows that it is seen the homogeneity of the groups.

In general, after the surgical intervention, an improvement in sexual function was observed in both groups of examined patients, a significant increase ($p < 0.05$) in satisfaction with sexual intercourse and overall satisfaction according to the IIEF scale was revealed (table 3).

Surgery on the penis enlargement contributed to the normalization of the depressive state of men in the form of a significant decrease in the HDRS score from 18.4 ± 2.2 at the beginning of the examination to 7.3 ± 2.6 after 6 months in the first

TABLE 1. IIEF Primary Indicators

| Indicator | 1st group(n = 38) | 2nd group (n = 36) |
|-------------------------------|-------------------|--------------------|
| Erectile function | 10,1 ± 2,0 | 9,8 ± 2,2 |
| Satisfaction with intercourse | 6,8 ± 2,3 | 6,6 ± 2,0 |
| Orgasm | 6,3 ± 1,8 | 6,5 ± 1,4 |
| Libido | 7,3 ± 1,6 | 7,5 ± 1,2 |
| Overall satisfaction | 5,4 ± 1,3 | 5,5 ± 1,2 |

TABLE 2. Primary indicators of HDRS and psychopathological symptoms

| Indicator | 1st group(n = 38) | 2nd group(n = 36) |
|------------------------------|-------------------|-------------------|
| Average HDRS, score | 18,4 ± 2,2 | 18,1 ± 2,6 |
| Emotional distress, abs./% | 30 (78,4%) | 28 (77,8%) |
| Depressive reactions, abs./% | 32 (84,2%) | 26 (72,2%) |
| Neurasthenia, abs./% | 19 (50%) | 19 (52,8%) |

TABLE 3. Dynamics of IIEF indicators in examined patients

| | 1st group(n = 38) | 2nd group(n = 36) |
|-------------------------------|-------------------|-------------------|
| Before treatment | | |
| Erectile function | 10,1 ± 2,0 | 9,8 ± 2,2 |
| Satisfaction with intercourse | 6,8 ± 1,3 | 6,6 ± 1,0 |
| Orgasm | 6,3 ± 1,8 | 6,5 ± 1,4 |
| Libido | 8,3 ± 1,6 | 8,5 ± 1,2 |
| Overall satisfaction | 5,4 ± 1,3 | 5,5 ± 1,2 |
| In 2 months | | |
| Erectile function | 18,2 ± 1,8* | 17,9 ± 2,2* |
| Satisfaction with intercourse | 10,4 ± 1,3* | 10,2 ± 1,7* |
| Orgasm | 6,8 ± 1,6 | 6,9 ± 1,4 |
| Libido | 8,2 ± 1,4 | 8,6 ± 1,2 |
| Overall satisfaction | 7,9 ± 1,5 | 7,5 ± 1,8 |
| In 6 months | | |
| Erectile function | 24,6 ± 1,4** | 23,1 ± 1,2** |
| Satisfaction with intercourse | 13,8 ± 1,1** | 13,6 ± 1,3** |
| Orgasm | 7,6 ± 1,1 | 7,8 ± 1,4 |
| Libido | 8,5 ± 1,3 | 8,9 ± 1,1 |
| Overall satisfaction | 9,3 ± 0,5** | 9,4 ± 0,4** |

Note: * – statistically significant differences ($p < 0.05$) between the initial values and after 2 months;

** – statistically significant differences ($p < 0.05$) between the initial values and after 6 months

group and from 18.1 ± 2.6 to 7.4 ± 2.3 , respectively, in the second group (Fig. 3).

In the first group, while using a collagen-like matrix made of polymerized polylactic acid impregnated with own stem cells in 38 patients we did not encounter complications that caused the removal of the matrix (table 4). In 2 patients, there was a small skin defect at the edge of the matrix. In one patient, the defect healed

spontaneously within 1 month with stimulation along the edges of VEGF; in one patient, circumcision with skin plastic was performed to close the defect. In 5 patients additional injections of polylactic acid gel were required between 6 and 36 months to optimize the shape or volume of the penis. 34 (89.5%) patients noted an improvement in sexual function and sexual sensations of a partner, harmonization of

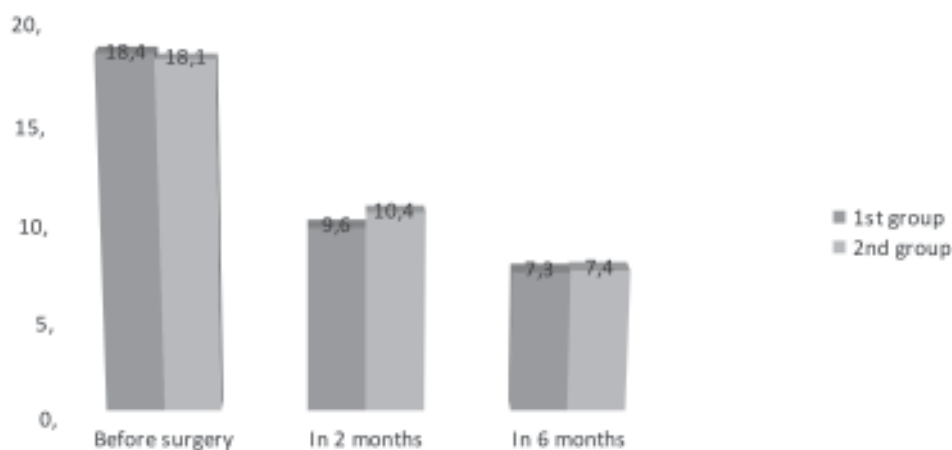


FIGURE 3. Dynamics of HDRS scores in examined patients: * - statistically significant differences ($p < 0.05$) between the initial values and after 2 months; ** - statistically significant differences ($p < 0.05$) between the initial values and after 6 months

TABLE 4. Evaluation of the effectiveness of treatment of patients with penile dysmorphophobia

| | Reducing the level of neurotic manifestations, abs./% | Harmonization of relations with a partner, abs./% | Increasing the level of self-sufficiency, abs./% |
|------------------|---|---|--|
| 1st group (n=38) | 34 (89,5%) | 34 (89,5%) | 36 (94,8%) |
| 2nd group (n=36) | 33 (91,7%) | 27 (75%) | 31 (86,1%) |
| Total (n=74) | 67 (90,5%) | 61 (82,4%) | 67 (90,5%) |

relationships in a couple, and 36 (94.8%) men – an increase in a sense of self-sufficiency and self-confidence.

When implanting a silicone implant, most patients – 31 (86.1%) are satisfied with the result, 27 (75%) patients note an improvement in sexual life, 31 (86.1%) also note an increase in their own self-sufficiency. At the same time, some patients noted the following complications: 2 patients noted displacement of the silicone matrix, 1 patient noted prolapse of the matrix, 1 patient noted a decrease in erection (which did not improve after removal of the matrix), in 1 case the silicone implant had to be removed due to the fact that the patient did not like the appearance.

CONCLUSIONS

Висновки

Modern implants can improve the size and appearance of the penis, improve the quality of sexual life (82.4%) and the feeling of self-sufficiency in operated men (90.5%) and help to normalize their depressive state.

The use of silicone implants is simpler, almost does not require specific rehabilitation after surgery, however, some patients experience prolapse of the

prosthesis and dissatisfaction with the final result. The use of a polymer matrix impregnated with one's own stem cells requires a special laboratory, more time for preoperative preparation and postoperative rehabilitation, however, it is more physiological and can be considered as a standard for safe penis enlargement.

СПИСОК ЛІТЕРАТУРИ

References

1. Austoni E., Guarneri A., Gatti G. Penile elongation and thickening – a myth? Is there a cosmetic or medical indication? *Andrologia*. 1999. 31(1). 45–51. Doi: 10.1111/j.1439-0272.1999.tb01450.x.
2. Campbell J., Gillis J. A review of penile elongation surgery. *Transl Androl Urol*. 2017. 6(1). 69–78. Doi: 10.21037/tau.2016.11.19.
3. Hatipoplu N., Kurtoplu S. Micropenis: etiology, diagnosis and treatment approaches. *J Clin Res Pediatr Endocrinol*. 2013. 5(4). 217–223. Doi: 10.4274/Jcrpe.1135.
4. Levine L.A., Newell M. M. FastSize™ Medical Extender for the treatment of Peyronie's disease. *Expert Rev. Med. Devices*. 2008. 5. 305–310.

5. Nikoobakht M., Shahnazari A., Rezaeidanesh M., Mehrsai A., Pourmand G. Effect of penile-extender device in increasing penile size in men with shortened penis: preliminary results. *J Sex Med.* 2011. 8(11). 3188–3192. Doi: 10.1111/j.1743-6109.2009.01662.x.

6. Nowroozi M.R., Amini E., Ayati M., Jamshidian H., Radkhah K., Amini S. Applying extender devices in patients with penile dysmorphophobia: assessment of tolerability, efficacy, and impact on erectile function. *J Sex Med.* 2015. 12(5). 1242–1247. Doi: 10.1111/jsm.12870.

7. Prause N., Park J., Leung S., Miller G. Women's Preferences for Penis Size: A New Research Method Using Selection among 3D Models. *PLoS One.* 2015. 2(10). Doi: 10.1371/journal.pone.0133079.

8. Soubra A., Natale C., Brimley S., Hellstrom W.J.G. Revelations on Men Who Seek Penile Augmentation Surgery: A Review. *Sex Med Rev.* 2021. 9. 84–86. Doi: 10.1016/j.sxmr.2021.10.003.

9. Spyriounis P.K., Karmiris N.I. Partial penile reconstruction following fat augmentation with anterolateral thigh perforator flap. *J Plast Reconstr Aesthet Surg.* 2012. 65(1). 15–17. Doi: 10.1016/j.bjps.2011.07.025.

10. Tealab A.A., Maarouf A.M., Habous M., Ralph D.J., Abohashem S. The use of an acellular collagen matrix in penile augmentation: A pilot study in Saudi Arabia. *Arab J Urol.* 2013. 11(2). 169–173. Doi: 10.1016/j.aju.2013.02.001.

11. Veale D., Miles S., Read J., Troglia A., Carmona L., Fiorito C., Wells H., Wylie K., Muir G. Penile Dysmorphic Disorder: Development of a Screening Scale. *Arch Sex Behav.* 2015. 44(8). 2311–2321. Doi: 10.1007/s10508-015-0484-6.

12. Yang D.Y., Ko K., Lee S.H., Lee W.K. A Comparison of the Efficacy and Safety between Hyaluronic Acid and Poly lactic Acid Filler Injection in Penile Augmentation: A Multicenter, Patient/Evaluator-Blinded, Randomized Trial. *J Sex Med.* 2019. 16(4). 577–585. Doi: 10.1016/j.jsxm.2019.01.310.

13. Yuan J., Hoang A.N., Romero C.A., Lin H., Dai Y., Wang R. Vacuum therapy in erectile dysfunction—science and clinical evidence. *Int J Impot Res.* 2010. 22(4). 211–219. Doi: 10.1038/ijir.2010.4.

14. Zhang X., Huang Z., Xiao Y., Kuang L., Zhang M., Zhang G., Li Q., Bai W., Xu T. Suspensory ligament release combined with acellular dermal matrix filler in infrapubic space: A new method for penile length augmentation. *Andrologia.* 2019. 51(9). Doi: 10.1111/and.13351.

REFERENCES

Список літератури

1. Austoni, E., Guarneri, A., & Gatti, G. (1999). Penile elongation and thickening — a myth? Is there a cosmetic or medical indication? *Andrologia*, 31(1), 45–51. Doi: 10.1111/j.1439-0272.1999.tb01450.x.

2. Campbell, J., & Gillis, J. (2017). A review of penile elongation surgery. *Transl Androl Urol.*, 6(1), 69–78. Doi: 10.21037/tau.2016.11.19.

3. Hatipoplu, N., & Kurtoplu, S. (2013). Micropenis: etiology, diagnosis and treatment approaches. *J Clin Res Pediatr Endocrinol.*, 5(4), 217–223. Doi: 10.4274/Jcrpe.1135.

4. Levine, L.A., Newell, M.M. (2008). FastSize™ Medical Extender for the treatment of Peyronie's disease. *Expert Rev. Med. Devices*, 5, 305–310.

5. Nikoobakht, M., Shahnazari, A., Rezaeidanesh, M., Mehrsai, A., & Pourmand, G. (2011). Effect of penile-extender device in increasing penile size in men with shortened penis: preliminary results. *J Sex Med.*, 8(11), 3188–3192. Doi: 10.1111/j.1743-6109.2009.01662.x.

6. Nowroozi, M.R., Amini, E., Ayati, M., Jamshidian, H., Radkhah, K., & Amini, S. (2015). Applying extender devices in patients with penile dysmorphophobia: assessment of tolerability, efficacy, and impact on erectile function. *J Sex Med.*, 12(5), 1242–1247. Doi: 10.1111/jsm.12870.

7. Prause, N., Park, J., Leung, S., & Miller, G. (2015). Women's Preferences for Penis Size: A New Research Method Using Selection among 3D Models. *PLoS One.*, 2(10). Doi: 10.1371/journal.pone.0133079.

8. Soubra, A., Natale, C., Brimley, S., & Hellstrom, W.J.G. (2021). Revelations on Men Who Seek Penile Augmentation Surgery: A Review. *Sex Med Rev.*, 9, 84–86. Doi: 10.1016/j.sxmr.2021.10.003.

9. Spyriounis, P.K., & Karmiris, N.I. (2012). Partial penile reconstruction following fat augmentation with anterolateral thigh perforator flap. *J Plast Reconstr Aesthet Surg.*, 65(1), 15–17. Doi: 10.1016/j.bjps.2011.07.025.

10. Tealab, A.A., Maarouf, A.M., Habous, M., Ralph, D.J., & Abohashem, S. (2013). The use of an acellular collagen matrix in penile augmentation: A pilot study in Saudi Arabia. *Arab J Urol.*, 11(2), 169–173. Doi: 10.1016/j.aju.2013.02.001.

11. Veale, D., Miles, S., Read, J., Troglia, A., Carmona, L., Fiorito, C., Wells, H., Wylie, K., & Muir, G. (2015). Penile Dysmorphic Disorder: Development of a Screening Scale. *Arch Sex Behav.*, 44(8), 2311–2321. Doi: 10.1007/s10508-015-0484-6.

12. Yang, D.Y., Ko, K., Lee, S.H., & Lee, W.K. A (2019). Comparison of the Efficacy and Safety between Hyaluronic Acid and Poly lactic Acid Filler Injection in Penile Augmentation: A Multicenter, Patient/Evaluator-Blinded, Randomized Trial. *J Sex Med.*, 16(4), 577–585. Doi: 10.1016/j.jsxm.2019.01.310.

13. Yuan, J., Hoang, A.N., Romero, C.A., Lin, H., Dai, Y., & Wang, R. (2010). Vacuum therapy in erectile dysfunction—science and clinical evidence. *Int J Impot Res.*, 22(4), 211–219. Doi: 10.1038/ijir.2010.4.

14. Zhang, X., Huang, Z., Xiao, Y., Kuang, L., Zhang, M., Zhang, G., Li, Q., Bai, W., & Xu, T. (2019). Suspensory ligament release combined with acellular dermal matrix filler in infrapubic space: A new method for penile length augmentation. *Andrologia*, 51(9). Doi: 10.1111/and.13351.

РЕФЕРАТ

Порівняння імплантаційних методів збільшення статевого члена

І.Е. Агиляр, О.В. Книгавко,
Д.М. Чой, К. Санджін

Незадоволеність чоловіка розміром статевого члена є найчастішим проявом пенільної дисморфофобії. Незважаючи на різноманітність методів збільшення статевого члена, досі не розроблено єдиної безпечної методики, яка б задовольняла пацієнтів.

Метою роботи стало порівняння результатів комбінованої операції зі встановлення силіконового імпланту або колагеноподібної матриці, просоченої аутологічними стовбуровими клітинами з одночасною лігаментотомією для збільшення довжини та окружності статевого члена.

У 2017-2022 роках у 2 спеціалізованих центрах виконано операції зі збільшення статевого члена. У КНП ХОР «ОМКЦУН ім. В. І. Шаповала» (Харків, Україна) у 38 пацієнтів з України та Польщі професором Книгавком О. В. здійснено імплантацію пористої матриці Max Pol (виробництва Dersmithson, M. D. Choi), і в «Mexico phalloplastic center» (Mexico-city, Mexico) у 36 пацієнтів Dr. Aguilar E. I. встановлені силіконові імпланти, що не розсмоктуються. Результати збільшення статевого члена оцінювалися у ранні (2 місяці) та віддалені (6 місяців) терміни.

При імплантації силіконового імпланту більшість пацієнтів – 31 (86,1%) були задоволені результатом, 27 (75%) пацієнтів відзначили покращення статевого життя, а у 31 (86,1%) збільшилося відчуття власної самодостатності. У

той же час частина пацієнтів відзначила наступні ускладнення: у 2 (5,6%) пацієнтів відбулося зміщення силіконової матриці, у 1 (2,8%) – пролабація матриці, 1 (2,8%) пацієнт відчув зниження ерекції (стан не поліпшився після видалення матриці), ще в 1 (2,8%) випадку довелося видалити силіконовий імплант через незадовільний, на думку пацієнта, зовнішній вигляд.

При використанні колагеноподібної матриці з полімеризованої полімолочної кислоти, просоченої власними стовбуровими клітинами у 38 пацієнтів ми не зустріли ускладнень, які б спричинили видалення матриці. Однак 5 (13,2%) пацієнтам у терміни від 6 до 36 місяців потребували додаткові ін'єкції гелю полімолочної кислоти для оптимізації форми або об'єму статевого члена. 34 (89,5%) пацієнти відзначили покращення статевої функції, сексуального відчуття партнерки та гармонізації стосунків у парі, а у 36 (97,4%) чоловіків підвищилося почуття самодостатності.

Таким чином, сучасні імпланти дозволяють покращити розмір та вид статевого члена, підвищити якість статевого життя та почуття самодостатності у прооперованих чоловіків. Використання силіконових імплантів простіше, майже не потребує специфічної реабілітації після операції, однак у частини пацієнтів відзначається пролабація протезу та незадоволеність кінцевим результатом. Використання полімерної матриці, просоченої власними стовбуровими клітинами, вимагає спеціальної лабораторії, більшого часу періопераційної підготовки та післяопераційної реабілітації, проте більш фізіологічно, і може розглядатися як стандарт безпечного збільшення статевого члена.

Ключові слова: збільшення статевого члена, довжина та коло статевого члена, силіконовий імплант, пориста матриця полімолочної кислоти, аутологічні стовбурові клітини, фактор зростання ендотелію судин.